

Role of HPV in Head and Neck Cancer

Margaret A. Stanley

Department of Pathology, University of Cambridge, Cambridge, UK.

ABSTRACT: The evidence is that infection with high-risk human papillomavirus (HRHPV), particularly HPV 16, is the cause of the increase in incidence over the past 2–3 decades, in economically developed countries, of oropharyngeal squamous cell carcinoma (OPSCC), a subset of head and neck squamous cell carcinomas (HNSCC). HRHPV DNA sequences are detected in HNSCC with tonsil and base of tongue, the sites with the highest prevalence of HPV+ve carcinomas. HRHPV E6/E7 mRNA oncogene expression and p16^{INK4A} overexpression (a marker of HRHPV E7 overexpression) are detected in 50–80% of OPSCC depending on geographical locale. Evidence from in vitro studies with oral keratinocyte cell lines and E6/E7 transgenic mice shows that E6/E7 oncogene expression is required for initiation and maintenance of the malignant phenotype. Case–control and cohort studies show that risk for OPSCC is associated with HPV exposure prior to cancer diagnosis. The experimental and epidemiological data provide robust evidence for a causal role in OPSCC, but the evidence for association of HPV with other HNSCC such as oral cavity or larynx is weak.

KEYWORDS: head and neck cancer, oropharyngeal squamous cell cancer, HPV, causality, epidemiology molecular markers

CITATION: Stanley. Role of HPV in Head and Neck Cancer. *Advances in Tumor Virology* 2014;4 1–6 doi:10.4137/ATV.S12435.

RECEIVED: February 2, 2014. **RESUBMITTED:** March 26, 2014. **ACCEPTED FOR PUBLICATION:** March 28, 2014.

ACADEMIC EDITOR: Frank J. Jenkins, Editor in Chief

TYPE: Review

FUNDING: Author discloses no funding sources.

COMPETING INTERESTS: MS has received speaker's fees from Merck Vaccines and consultancy fees from SPMSD and GSK Biologicals.

COPYRIGHT: © the authors, publisher and licensee Libertas Academica Limited. This is an open-access article distributed under the terms of the Creative Commons CC-BY-NC 3.0 License.

CORRESPONDENCE: mas1001@cam.ac.uk

Introduction

Human papillomaviruses (HPVs) are a large family of small, double-stranded DNA viruses that infect the squamous epithelia of the skin and internal mucosal surfaces of the anogenital and upper respiratory tracts. HPVs are classified as genotypes as determined by the sequence of the gene encoding the major capsid protein L1 and numbered in the order in which they were isolated: HPV 1, HPV 2, etc. About 30–40 HPV types regularly or sporadically infect the squamous mucosal surfaces of the anogenital tract and these mucosotropic types can be classified into two groups:

1. Low-risk viruses that cause genital warts or Condyloma acuminata, the most prevalent types are HPV 6 and 11.
2. High-risk or oncogenic viruses associated with malignant disease. Thirteen of these types are recognized as oncogenic.

Infection with an oncogenic HPV type is the cause of cervical cancer in women.¹ Globally, HPV 16 is the most

commonly detected type (55% of cases) followed by HPV 18 (15% of cases). Other oncogenic types, 31, 33, 35, 45, 52, and 58, comprise a further 18% of cases. In addition, squamous cell cancers of the anus, vulva, vagina, penis, and head and neck have an HPV attributable fraction.² HPV 16 is the most prevalently detected type in these other sites. Defining the contribution of HPV to the etiology of head and neck cancer is complicated by the fact that in comparison to the cervix and anogenital sites, at which HPV has been shown to play a role,² the head and neck is anatomically and histologically complex including the oral cavity, oropharynx, hypopharynx, nasopharynx, nasal sinuses, larynx, and trachea (Fig. 1). At all these sites, squamous cell carcinomas (SCCs) amount to more than 90% of malignancies and there is a strong and synergistic association with tobacco smoking and alcohol abuse in their development.^{3,4}

However, recent trends in incidence differ for these sites. In England, over the period 1990–2006, the incidence of SCC of the oral cavity, the naso pharynx, hypopharynx, and larynx either increased slightly or stabilized, possibly as a consequence of the decline in the smoking habit.⁵ In contrast,

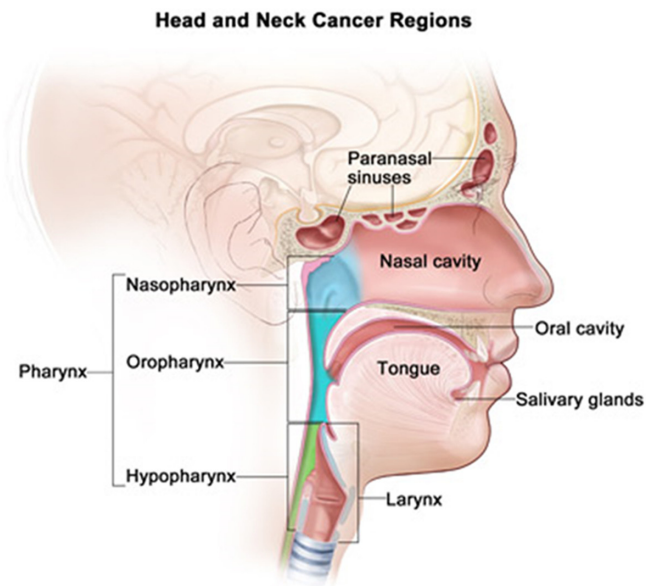


Figure 1. Cancers of the head and neck are classified according to the area of the head or neck from which they arise. The majority begins in the squamous cells that line the moist, mucosal surfaces inside the head and neck, and these are referred to as HNSCC.

the incidence of oropharyngeal squamous cell carcinoma (OPSCC) more than doubled over this period. OPSCC shows a greater increase in incidence than any other head and neck cancer over the previous decade in England and this situation is mirrored in most developed countries.⁶ The evidence that is accruing, strongly implicates infection with HPV as the primary causative factor in a subset of oropharyngeal carcinomas^{6,7} with perhaps a minor attributable fraction at other sites in the head and neck.⁸

HPV Infection and HNSCC—Causality or Coincidence

Establishing causality for an infectious agent in cancer is not straightforward. Cancer is a chronic disease, a multistage phenomenon with usually an interval of decades between exposure to the infectious agent and the eventual emergence of clinical disease. However, molecular and experimental evidence⁹ and epidemiological criteria as articulated by Hill¹⁰ (strength, consistency, specificity, temporality, biological plausibility, and coherence) can, in combination, provide robust evidence for an etiological association.

Molecular and Experimental Studies

HPV DNA is detected in a subset of HNSCC. HPV cannot be grown efficiently in in-vitro culture and HPV infection is determined usually by detection of HPV DNA in swabs or scrapes or biopsies using sensitive molecular hybridization methods.¹¹ Amplification of target DNA sequences by polymerase chain reaction (PCR) followed by hybridization with type-specific probes is the most widely

used method.¹² Using such methods, HPV DNA has been detected in HNSCC arising at several sites in the head and neck (reviewed in Ref.¹³). These studies show that prevalence is higher in OPSCC (35%) compared with SCC of the oral cavity (25%) or larynx (24%). Levels of HPV DNA prevalence in OPSCC as detected by PCR have varied considerably with levels up to 90% in some studies,¹⁴ although they are on average 50–60%.^{15,16} Among HPV+ve OPSCC, HPV 16 is the most prevalent accounting for 90% or more of cases.¹⁷ The extreme sensitivity of PCR-based DNA detection methods that are capable of detecting less than one genome copy per cell raises the question of the relevance of detecting such low viral loads—when very low genome copies are detected is HPV really causal? The virus could be a passenger or a contaminant and have nothing to do with the oncogenic process. However, in studies in which PCR has been combined with in situ hybridization, a less-sensitive but cell-specific methodology, HPV DNA is present as diffuse staining both in malignant cells throughout the lesion^{18,19} and also in intraepithelial lesions adjacent to the invasive cancer¹⁹ arguing against contamination in these cases. Furthermore, as in cervical cancer, HPV genomes are integrated into the host genome, in many tonsillar cancer cases,^{19–21} implying clonality.

High-risk HPV oncogene expression and initiation and maintenance of the malignant phenotype. The detection of viral DNA in the malignant cells however is not unequivocal proof of causality. The question is whether there is viral gene expression and whether that viral gene expression is necessary for the initiation and maintenance of the tumor phenotype. The E6/E7 genes of the high-risk HPV (HRHPVs) are potent oncogenes. E6 binds to TP53 targeting it for ubiquitination, E7 binds to unphosphorylated pRB thereby disabling the G1/S cell cycle checkpoint, and the combined action of E6/E7 leads to loss of cell cycle control, inhibition of apoptosis, and chromosomal instability. The deregulation and consistent expression of HRHPV E6/E7 is required for the initiation and maintenance of the malignant phenotype in cervical carcinogenesis.²² There is evidence that this applies also to HPV+ve HNSCC. In vitro studies have shown that oropharyngeal and tonsillar keratinocytes are immortalized by full-length HPV 16 DNA and/or E6/E7 and that the E6/E7 genes are expressed.^{23–25} Knockdown experiments show that inhibition of E6/E7 in HPV+ve oropharyngeal cancer cells results in apoptosis and restoration of the P53 and RB pathways that are the target for E6 and E7.^{26,27} Mice transgenic for HPV 16 E6/E7 under the control of tissue-specific promoters exhibit abnormal epithelial proliferations in the oral cavity and oropharynx that progress, after exposure to low doses of the chemical carcinogen 4NQO, to HNSCC.²⁸ These tumors are HPV 16 DNA+ve, show HPV 16 E6/E7 expression and overexpression of P16^{INK4A} triggered by the deregulation of E7 expression, and induction of the histone demethylase KDM6B.²⁹



Expression of HPV E6/E7 mRNA, the gold standard for HPV infection, is less common in HNSCC than PCR-based DNA detection^{30,31} with about 14–50%^{32–34} of HPV DNA+ve tumors negative for HPV E6/E7 expression. HPV E6/E7+ve tumors show other markers associated with HPV viral gene expression and HPV-mediated carcinogenesis. Thus, HNSCC displaying E6/E7 expression is positive for P16^{INK4A} immunostaining³⁵ and there is a strong correlation between P16^{INK4A} overexpression and HPV status in OPSCC, although it is not absolute. E6/E7+ve HNSCC show chromosomal abnormalities in common with cervical carcinogenesis³⁶ with imbalances at 3p, 9p and 7p.^{30,37} In contrast to E6/E7 mRNA–ve HNSCC, E6/E7+ve tumors have wtTP53.^{18,37–39} Furthermore, E6/E7+ve tumors are characterized by distinct microarray gene expression profiles,^{40–42} fewer somatic mutations,⁴³ and distinct small microRNA patterns.⁴⁴

Epidemiology

Case–control and cohort studies have evaluated the association between the risk for HNSCC and several measures of HPV infection or exposure including serology, sexual behavior, and the detection of HPV DNA in oral cells.

HPV 16 L1 seropositivity and risk for HNSCC. Seroconversion following HPV infection in the anogenital tract is not always observed with an average of 40–70% women⁴⁵ and 4–36% men⁴⁶ developing antibody to the major capsid protein L1. However, these antibodies persist over many years and large seroepidemiological studies suggest that the L1 seropositivity is a surrogate for the lifetime cumulative exposure to HPV infection.⁴⁷ HPV 16 is the most frequently detected HPV genotype in HNSCC tumors and most studies have evaluated HPV 16 seroreactivity and HNSCC risk either overall and/or for SCCs at one or more anatomical subsites.^{15,48–56} Odds Ratio's (OR's) for HNSCC and HPV 16 L1 seropositivity vary from 1.7 to 7.5 but almost without exception when different cancer subsites in the head and neck and HPV L1 serology are evaluated, much stronger associations with OPSCC, particularly tonsillar and base of tongue cancer, are reported than that for oral or laryngeal cancers (for review see Ref.⁵⁷). In a nested case–control studies in the Nordic countries,⁵⁸ serum samples were prospectively collected from 292 individuals who subsequently developed HNSCC and from 1568 age- and sex-matched controls. For HNSCC, overall, HPV 16 seropositive subjects had an OR > 2, for OPSCC > 14, for tongue cancer > 3, for laryngeal cancer > 2. This study was adjusted for tobacco use by measuring serum cotinine levels. Crucially, since increased risk occurred up to 15 years before cancer diagnosis, it can be inferred that HPV infection preceded cancer development.

HPV 16 E6/E7 serology and risk for HNSCC. Serum antibodies to the early proteins E6 and E7 of the HRHPVs are rarely detected in subjects with cervical intraepithelial neoplasia of any grade but can be detected in a proportion of

subjects with invasive cervical cancer.⁵⁹ Recent studies suggest that HPV 16 E6 seropositivity in particular is associated with a subset of HNSCC, particularly OPSCC and that this seroreactivity precedes the diagnosis.⁶⁰ HPV 16 antibodies are present in a significant proportion of patients, 35%, with OPSCC many years before disease but are rare in controls 0.6%. These data are comparable with those from other large studies.^{56,61} The most recent of these involved 1425 controls, 0.8% of which were E6 seropositive, and 324 patients, 30% of whom were E6 seropositive.⁶¹

HPV DNA in exfoliated oral epithelial cells. Most studies have found an association between the detection of HRHPV DNA in exfoliated oral epithelial cells and HNSCC risk.⁶² Associations are much higher for OPSCC than oral cavity and other sites.^{55,63} There are methodological and classification issues for these studies. A variety of sampling techniques have been used to collect cells; oral rinses, swabbing, or scraping the oral cavity and oropharynx with cotton tip buds or toothbrushes potentially resulting in variability in the samples. The DNA detection methods also vary in sensitivity and specificity, and misclassification of cancers according to subsite cannot be excluded. Overall case–control studies show a consistent association between HPV infection (as determined by DNA detection) and OPSCC but the association with other subsites remains to be defined.⁶²

Sexual behavior associations. The strongest environmental associations for HNSCC are tobacco use, high alcohol intake, and poor dentition.⁶⁴ High-risk mucosotropic HPV infection is sexually transmitted in the genital tract¹ and the consensus view is that this is true also for oral HPV infection. Measures of sexual behavior should therefore be a surrogate for oral HPV infection, and a number of case–control studies have evaluated sexual behaviors as a risk for HNSCC (for review see Ref.⁵⁷). The sexual behaviors most consistently associated are increasing number of lifetime sex partners and number of oral sex partners.⁶⁵ The cancer risk sites in the head and neck most strongly associated with sexual behavior are in the oropharynx specifically tonsil and base of tongue and these are the sites with the highest prevalence of HPV DNA detected in the tumors and evidence of HPV gene expression.⁶⁵

Trends in the Incidence of HNSCC

The evidence from both molecular experimental and epidemiological studies strongly supports a causal association between OPSCC, mainly tonsil and base of tongue, and HRHPV^{7,18} particularly HPV 16, but the role of HPV in other HNSCC sites such as the oral cavity cancer (OCC) is not proven.⁶⁶ Cancers of the oral cavity and of the oropharynx are the sixth commonest cancers worldwide with an estimated 400,000 cases per annum and 230,000 deaths.⁶⁷ Heavy tobacco and alcohol use and poor dentition are strong risk factors for both OCC and OPSCC.⁶⁸ The incidence of OCC has declined or stabilized in many parts of the world in the recent past and this coincides with the decline in tobacco

use in those localities.⁶⁴ In contrast, OPSCC incidence has increased in several countries predominantly in developed countries^{69–71} such as Northern Europe, Australia, and the USA. In those countries for which molecular data are available, that is Australia,⁷⁰ Sweden,⁷² and the USA,⁷³ these increases correlate strongly with increase in the proportion of HPV+ve OPSCC over the period from 1980 onward. The rise is greater, two- to threefold, in men than women and in contrast to HPV–ve cancers, HPV+ve OPSCC occur in younger age groups <60 years and are not associated strongly with tobacco or alcohol use.⁵⁴ A comprehensive analysis of worldwide trends in incidence of OPSCC and OCC has been published recently.⁶ To attempt to discriminate between tobacco use and HPV in causality, trends in SCC of the lung were evaluated in addition to oral cavity and oropharynx. These studies show that in developed countries such as the UK and the USA, HPV infection contributed to the dramatic rise in OPSCC over the period 1983–2002, particularly in men. However, the incidence of lung SCC in men declined over this time, supporting a role for factors other than smoking in OPSCC, such as HPV. There is evidence that sexual behaviors have changed among the recent birth cohorts in developed countries consistent with the younger age of patients with HPV+ve OPSCC.^{70,73} Furthermore, HPV prevalence in OPSCC differs between developed and developing countries. Thus, at present, 60–70% of OPSCC are associated with HPV infection in the USA,⁷³ 50–60% in the UK,¹⁶ but less than 10% in poorer countries.¹⁵

HPV Vaccines and HNSCC

The evidence for a causal role for HPV in OPSCC is strong, meeting the most important criteria enunciated by Bradford Hill,¹⁰ strength, consistence, and specificity but the most unequivocal evidence would be if prevention of HPV infection by vaccination prevented HPV+ve OPSCC. There are two licensed prophylactic HPV vaccines. These are Cervarix®, a bivalent HPV (bHPV) 16/18 product from GlaxoSmithKline Biologicals Rixensart, Belgium, and Gardasil® (also known as Silgard), a quadrivalent HPV (qHPV) 6, 11, 16, 18 product from MSD (Whitehouse Station, NJ, USA). These products are subunit protein vaccines comprising the HPV L1 coat protein assembled into virus-like particles. In randomized clinical trials (RCTs), both have shown efficacy >90% against vaccine HPV-type infection and benign and premalignant disease in the cervix, vagina, vulva, anus, and penis.⁷⁴ Since these systemically administered vaccines have reduced disease and infection at all the anogenital mucosal sites so far evaluated, it is likely that they will equally be effective against HPV-associated HNSCC. This speculation is supported by preliminary evidence from a population-based trial using the bHPV vaccine in Guanacaste Province Costa Rica in which prevalence of HPV 16 and 18 infection was reduced by 93% 4 years after vaccination.⁷⁵

Clinical Significance of HPV in HNSCC

OPSCC has two distinct etiologies, HPV infection or alcohol and tobacco use. Until recently, the significance of making this distinction with respect to the individual patient was not appreciated, but it is becoming evident that this is of clinical importance. HPV+ve OPSCC are associated with better response to chemotherapy, chemoradiotherapy, and radiotherapy than HPV–ve OPSCC and overall have a better prognosis.^{17,76–78} Furthermore, better outcomes have been reported for HPV+ve OPSCC after surgery, suggesting that the improved responses are independent of the treatment received.^{79,80}

Tissue Tropism, HPV, and HNSCC

The consensus view is that HPV is an established cause of OPSCC, predominantly of the tonsil and base of tongue, but that if it has a causal role at other anatomical sites in the head and neck, it is a minor one. Interestingly, the epithelia covering Waldeyers ring, the annular arrangement of lymphoid tissue in the pharynx do appear to be a target for viral carcinogenesis, with Epstein–Barr virus strongly associated with nasopharyngeal carcinoma and HPV with OPSCC (Fig. 2). Why should HPV target the squamous epithelia overlying the lingual and palatine tonsil but spare that of the oral cavity or the larynx? The other sites at which HPV is the most important etiological factor are the cervix (100% attributable cases) and the anus (>80% attributable cases).² Histologically, the cervix, anus, and lingual and palatine tonsil all display a squamocolumnar or squamomucosal junction, an abrupt switch from stratified squamous epithelial layer to a single layer of columnar epithelial cells. The cell and molecular biology of these junctional sites are poorly understood, but recent

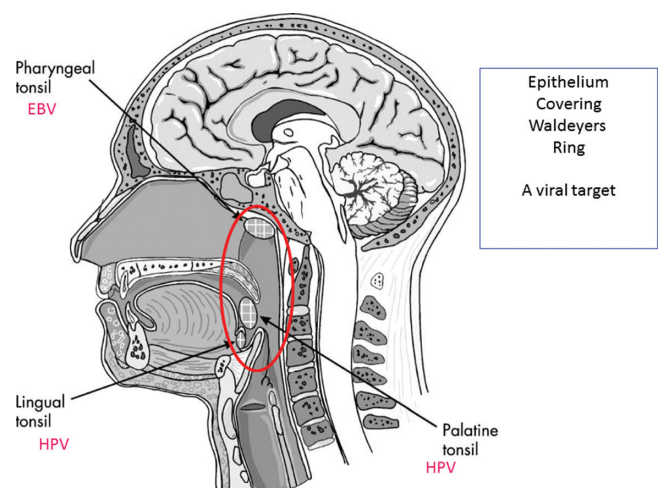


Figure 2. Waldeyers ring of lymphoid tissue circumscribes the naso and oropharynx with some of the tonsillar tissue located above and below the soft palate and to the back of the oral cavity. The epithelia overlying these sites appear to be susceptible to viral-mediated carcinogenesis with the oropharyngeal mucosa associated with HPV+ve cancers and the nasopharyngeal carcinoma associated with Epstein–Barr virus.



data from the cervix are relevant. Gene expression studies have revealed the presence at the cervical squamocolumnar junction of a subset of primitive embryonic cells defined by specific molecular markers.⁸¹ This expression profile is consistently shown in the high-grade cervical precancers (cervical intraepithelial neoplasia grade 3) and invasive cervical cancers strongly suggesting that this primitive cell subset is the target for HPV-mediated cervical carcinogenesis. Primitive cell subsets have been detected in the anus⁸¹ and at the esophageal gastric junction, and a major research question is whether a comparable subset of primitive cells exists in the tonsillar crypts, are the targets for HPV have an increased risk for the deregulation of HPV viral gene expression that drives the neoplastic process.⁸² These are important questions since it is likely that the deregulation of E6/E7 gene expression with the subsequent disruption of the cell cycle, inhibition of apoptosis, and chromosomal instability are generic mechanisms for HPV-mediated carcinogenesis at all sites but that the cofactors that contribute to that process differ at each site and may represent different targets for intervention.

Author Contributions

Conceived the concept: MS. Wrote the first draft of the manuscript: MS. Made critical revisions: MS. The author reviewed and approved of the final manuscript.

DISCLOSURES AND ETHICS

As a requirement of publication the author has provided signed confirmation of compliance with ethical and legal obligations including but not limited to compliance with ICMJE authorship and competing interests guidelines, that the article is neither under consideration for publication nor published elsewhere, of their compliance with legal and ethical guidelines concerning human and animal research participants (if applicable), and that permission has been obtained for reproduction of any copyrighted material. This article was subject to blind, independent, expert peer review. The reviewers reported no competing interests. Provenance: the author was invited to submit this paper.

REFERENCES

1. Moscicki AB, Schiffman M, Burchell A, et al. Updating the natural history of human papillomavirus and anogenital cancers. *Vaccine*. 2012;30(suppl 5):F24–F33.
2. Forman D, de Martel C, Lacey CJ, et al. Global burden of human papillomavirus and related diseases. *Vaccine*. 2012;30(suppl 5):F12–F23.
3. Gillison ML. Current topics in the epidemiology of oral cavity and oropharyngeal cancers. *Head Neck*. 2007;29(8):779–792.
4. Rietbergen MM, Leemans CR, Bloemena E, et al. Increasing prevalence rates of HPV attributable oropharyngeal squamous cell carcinomas in the Netherlands as assessed by a validated test algorithm. *Int J Cancer*. 2013;132(7):1565–1571.
5. Available at http://www.ncin.org.uk/cancer_type_and_topic_specific_work/cancer_type_specific_work/head_and_neck_cancers/head_and_neck_cancer_hub/resources. Accessed January, 2014.
6. Chaturvedi AK, Anderson WF, Lortet-Tieulent J, et al. Worldwide trends in incidence rates for oral cavity and oropharyngeal cancers. *J Clin Oncol*. 2013; 31(36): 4550–4559.
7. Bouvard V, Baan R, Straif K, et al. A review of human carcinogens—part B: biological agents. *Lancet Oncol*. 2009;10(4):321–322.
8. Lingner MW, Xiao W, Schmitt A, et al. Low etiologic fraction for high-risk human papillomavirus in oral cavity squamous cell carcinomas. *Oral Oncol*. 2013; 49(1):1–8.
9. zur Hausen H. Molecular pathogenesis of cancer of the cervix and its causation by specific human papillomavirus types. *Curr Top Microbiol Immunol*. 1994; 186:131–156.
10. Hill AB. The environment and disease: association or causation? *Proc R Soc Med*. 1965;58:295–300.
11. Poljak M, Cuzick J, Kocjan BJ, Iftner T, Dillner J, Arbyn M. Nucleic acid tests for the detection of alpha human papillomaviruses. *Vaccine*. 2012;30(suppl 5): F100–F106.
12. Mirghani H, Amen F, Moreau F, et al. Human papillomavirus testing in oropharyngeal squamous cell carcinoma: what the clinician should know. *Oral Oncol*. 2014;50:1–9.
13. Kreimer AR, Clifford GM, Boyle P, Franceschi S. Human papillomavirus types in head and neck squamous cell carcinomas worldwide: a systematic review. *Cancer Epidemiol Biomarkers Prev*. 2005;14(2):467–475.
14. Näsman A, Attner P, Hammarstedt L, et al. Incidence of human papillomavirus (HPV) positive tonsillar carcinoma in Stockholm, Sweden: an epidemic of viral-induced carcinoma? *Int J Cancer*. 2009;125(2):362–366.
15. Herrero R, Castellsagué X, Pawlita M, et al. Human papillomavirus and oral cancer: the International Agency for Research on Cancer multicenter study. *J Natl Cancer Inst*. 2003;95(23):1772–1783.
16. Evans M, Newcombe R, Fiander A, et al. Human papillomavirus-associated oropharyngeal cancer: an observational study of diagnosis, prevalence and prognosis in a UK population. *BMC Cancer*. 2013;13(1):220.
17. Dayyani F, Etzel CJ, Liu M, Ho CH, Lippman SM, Tsao AS. Meta-analysis of the impact of human papillomavirus (HPV) on cancer risk and overall survival in head and neck squamous cell carcinomas (HNSCC). *Head Neck Oncol*. 2010;2(1):15.
18. Gillison ML, Koch WM, Capone RB, et al. Evidence for a causal association between human papillomavirus and a subset of head and neck cancers. *J Natl Cancer Inst*. 2000;92(9):709–720.
19. Begum S, Cao D, Gillison M, Zahurak M, Westra WH. Tissue distribution of human papillomavirus 16 DNA integration in patients with tonsillar carcinoma. *Clin Cancer Res*. 2005;11(16):5694–5699.
20. Snijders PJ, Cromme FV, van denBrule AJ, et al. Prevalence and expression of human papillomavirus in tonsillar carcinomas, indicating a possible viral etiology. *Int J Cancer*. 1992;51(6):845–850.
21. Lace MJ, Anson JR, Klussmann JP, et al. Human papillomavirus (HPV)-16 genomes integrated in head and neck cancers and in HPV-16-immortalized human keratinocyte clones express chimeric virus-cell mRNAs similar to those found in cervical cancers. *J Virol*. 2010;85(4):1645–1654.
22. Doorbar J, Quint W, Banks L, et al. The biology and life-cycle of human papillomaviruses. *Vaccine*. 2012;30(suppl 5):F55–F70.
23. Park NH, Min BM, Li SL, Huang MZ, Cherick HM, Doniger J. Immortalization of normal human oral keratinocytes with type 16 human papillomavirus. *Carcinogenesis*. 1991;12(9):1627–1631.
24. Sexton CJ, Proby CM, Banks L, et al. Characterization of factors involved in human papillomavirus type 16 mediated immortalization of oral keratinocytes. *J Gen Virol*. 1993;74(pt 4):755–761.
25. Chen RW, Aalto Y, Teesalu T, et al. Establishment and characterisation of human papillomavirus type 16 DNA immortalised human tonsillar epithelial cell lines. *Eur J Cancer*. 2003;39(5):698–707.
26. Rampias T, Sasaki C, Weinberger P, Psyrri A. E6 and E7 gene silencing and transformed phenotype of human papillomavirus 16-positive oropharyngeal cancer cells. *J Natl Cancer Inst*. 2009;101(6):412–423.
27. Smeets SJ, van der Plas M, Schaij-Visser TB, et al. Immortalization of oral keratinocytes by functional inactivation of the p53 and pRb pathways. *Int J Cancer*. 2011;128(7):1596–1605.
28. Strati K, Pitot HC, Lambert PF. Identification of biomarkers that distinguish human papillomavirus (HPV)-positive versus HPV-negative head and neck cancers in a mouse model. *Proc Natl Acad Sci U S A*. 2006;103(38):14152–14157.
29. Strati K, Lambert PF. Role of Rb-dependent and Rb-independent functions of papillomavirus E7 oncogene in head and neck cancer. *Cancer Res*. 2007;67(24): 11585–11593.
30. van Houten VM, Snijders PJ, van denBrekkel MW, et al. Biological evidence that human papillomaviruses are etiologically involved in a subgroup of head and neck squamous cell carcinomas. *Int J Cancer*. 2001;93(2):232–235.
31. Jung AC, Briolat J, Millon R, et al. Biological and clinical relevance of transcriptionally active human papillomavirus (HPV) infection in oropharynx squamous cell carcinoma. *Int J Cancer*. 2010;126(8):1882–1894.
32. Smeets SJ, Hesselink AT, Speel EJ, et al. A novel algorithm for reliable detection of human papillomavirus in paraffin embedded head and neck cancer specimen. *Int J Cancer*. 2007;121(11):2465–2472.
33. Jordan RC, Lingner MW, Perez-Ordóñez B, et al. Validation of methods for oropharyngeal cancer HPV status determination in US cooperative group trials. *Am J Surg Pathol*. 2012;36(7):945–954.
34. Weinberger PM, Yu Z, Haffty BG, et al. Molecular classification identifies a subset of human papillomavirus-associated oropharyngeal cancers with favorable prognosis. *J Clin Oncol*. 2006;24(5):736–747.
35. Schlecht NF, Brandwein-Gensler M, Nuovo GJ, et al. A comparison of clinically utilized human papillomavirus detection methods in head and neck cancer. *Mod Pathol*. 2011;24(10):1295–1305.



36. Wilting SM, Smeets SJ, Snijders PJ, et al. Genomic profiling identifies common HPV-associated chromosomal alterations in squamous cell carcinomas of cervix and head and neck. *BMC Med Genomics*. 2009;2(1):32.
37. Braakhuis BJ, Snijders PJ, Keune WJ, et al. Genetic patterns in head and neck cancers that contain or lack transcriptionally active human papillomavirus. *J Natl Cancer Inst*. 2004;96(13):998–1006.
38. Dai M, Clifford GM, le Calvez F, et al. Human papillomavirus type 16 and TP53 mutation in oral cancer: matched analysis of the IARC multicenter study. *Cancer Res*. 2004;64(2):468–471.
39. Westra WH, Taube JM, Poeta ML, Begum S, Sidransky D, Koch WM. Inverse relationship between human papillomavirus-16 infection and disruptive p53 gene mutations in squamous cell carcinoma of the head and neck. *Clin Cancer Res*. 2008;14(2):366–369.
40. Slebos RJ, Yi Y, Ely K, et al. Gene expression differences associated with human papillomavirus status in head and neck squamous cell carcinoma. *Clin Cancer Res*. 2006;12(3 pt 1):701–709.
41. Schlecht NF, Burk RD, Adrien L, et al. Gene expression profiles in HPV-infected head and neck cancer. *J Pathol*. 2007;213(3):283–293.
42. Laborde RR, Novakova V, Olsen KD, Kasperbauer JL, Moore EJ, Smith DI. Expression profiles of viral responsive genes in oral and oropharyngeal cancers. *Eur J Cancer*. 2010;46(6):1153–1158.
43. Stransky N, Eglhoff AM, Tward AD, et al. The mutational landscape of head and neck squamous cell carcinoma. *Science*. 2011;333(6046):1157–1160.
44. John K, Wu J, Lee BW, Farah CS. MicroRNAs in head and neck cancer. *Int J Dent*. 2013;2013:650218.
45. Carter JJ, Koutsky LA, Hughes JP, et al. Comparison of human papillomavirus types 16, 18, and 6 capsid antibody responses following incident infection. *J Infect Dis*. 2000;181(6):1911–1919.
46. Edelstein ZR, Carter JJ, Garg R, et al. Serum antibody response following genital [alpha] 9 human papillomavirus infection in young men. *J Infect Dis*. 2011;204(2):209–216.
47. Olsen AO, Dillner J, Gjoen K, Magnus P. Seropositivity against HPV 16 capsids: a better marker of past sexual behaviour than presence of HPV DNA. *Genitourin Med*. 1997;73(2):131–135.
48. Dillner J, Knekt P, Schiller JT, Hakulinen T. Prospective seroepidemiological evidence that human papillomavirus type 16 infection is a risk factor for oesophageal squamous cell carcinoma. *BMJ*. 1995;311(7016):1346.
49. Dahlstrom KR, Adler-Storhiz K, Ertzel CJ, et al. Human papillomavirus type 16 infection and squamous cell carcinoma of the head and neck in never-smokers: a matched pair analysis. *Clin Cancer Res*. 2003;9(7):2620–2626.
50. Van Doornum GJ, Korse CM, Buning-Kager JC, et al. Reactivity to human papillomavirus type 16 L1 virus-like particles in sera from patients with genital cancer and patients with carcinomas at five different extragenital sites. *Br J Cancer*. 2003;88(7):1095–1100.
51. Smith EM, Ritchie JM, Pawlita M, et al. Human papillomavirus seropositivity and risks of head and neck cancer. *Int J Cancer*. 2007;120(4):825–832.
52. D'Souza G, Kreimer AR, Viscidi R, et al. Case-control study of human papillomavirus and oropharyngeal cancer. *N Engl J Med*. 2007;356(19):1944–1956.
53. Applebaum KM, Furniss CS, Zeka A, et al. Lack of association of alcohol and tobacco with HPV 16-associated head and neck cancer. *J Natl Cancer Inst*. 2007;99(23):1801–1810.
54. Gillison ML, D'Souza G, Westra W, et al. Distinct risk factor profiles for human papillomavirus type 16-positive and human papillomavirus type 16-negative head and neck cancers. *J Natl Cancer Inst*. 2008;100(6):407–420.
55. Pintos J, Black MJ, Sadeghi N, et al. Human papillomavirus infection and oral cancer: a case-control study in Montreal, Canada. *Oral Oncol*. 2008;44(3):242–250.
56. Ribeiro KB, Levi JE, Pawlita M, et al. Low human papillomavirus prevalence in head and neck cancer: results from two large case-control studies in high-incidence regions. *Int J Epidemiol*. 2011;40(2):489–502.
57. Gillison ML, Alemany L, Snijders PJ, et al. Human papillomavirus and diseases of the upper airway: head and neck cancer and respiratory papillomatosis. *Vaccine*. 2012;30(suppl 5):F34–F54.
58. Mork J, Lie AK, Glatte E, et al. Human papillomavirus infection as a risk factor for squamous-cell carcinoma of the head and neck. *N Engl J Med*. 2001;344(15):1125–1131.
59. Lehtinen M, Pawlita M, Zumbach K, et al. Evaluation of antibody response to human papillomavirus early proteins in women in whom cervical cancer developed 1 to 20 years later. *Am J Obstet Gynecol*. 2003;188(1):49–55.
60. Kreimer AR, Johansson M, Waterboer T, et al. Evaluation of human papillomavirus antibodies and risk of subsequent head and neck cancer. *J Clin Oncol*. 2013;31(21):2708–2715.
61. Anantharaman D, Gheit T, Waterboer T, et al. Human papillomavirus infections and upper aero-digestive tract cancers: the ARCADE study. *J Natl Cancer Inst*. 2013;105(8):536–545.
62. Syrjänen S, Lodi G, von Bültzingslöwen I, et al. Human papillomaviruses in oral carcinoma and oral potentially malignant disorders: a systematic review. *Oral Dis*. 2011;17(suppl 1):58–72.
63. Tachezy R, Klozar J, Rubenstein L, et al. Demographic and risk factors in patients with head and neck tumors. *J Med Virol*. 2009;81(5):878–887.
64. Franceschi S, Bidoli E, Herrero R, Munoz N. Comparison of cancers of the oral cavity and pharynx worldwide: etiological clues. *Oral Oncol*. 2000;36(1):106–115.
65. Heck JE, Berthiller J, Vaccarella S, et al. Sexual behaviours and the risk of head and neck cancers: a pooled analysis in the International Head and Neck Cancer Epidemiology (INHANCE) consortium. *Int J Epidemiol*. 2010;39(1):166–181.
66. de Martel C, Ferlay J, Franceschi S, et al. Global burden of cancers attributable to infections in 2008: a review and synthetic analysis. *Lancet Oncol*. 2012;13(6):607–615.
67. Ferlay J, Shin HR, Bray F, Forman D, Mathers C, Parkin DM. Estimates of worldwide burden of cancer in 2008: GLOBOCAN 2008. *Int J Cancer*. 2010;127(12):2893–2917.
68. Hashibe M, Boffetta P, Zaridze D, et al. Contribution of tobacco and alcohol to the high rates of squamous cell carcinoma of the supraglottis and glottis in Central Europe. *Am J Epidemiol*. 2007;165(7):814–820.
69. Marur S, D'Souza G, Westra WH, Forastiere AA. HPV-associated head and neck cancer: a virus-related cancer epidemic. *Lancet Oncol*. 2010;11(8):781–789.
70. Hong AM, Grulich AE, Jones D, et al. Squamous cell carcinoma of the oropharynx in Australian males induced by human papillomavirus vaccine targets. *Vaccine*. 2010;28(19):3269–3272.
71. Chaturvedi AK. Epidemiology and clinical aspects of HPV in head and neck cancers. *Head Neck Pathol*. 2012;6(suppl 1):16–24.
72. Hammarstedt L, Lindquist D, Dahlstrand H, et al. Human papillomavirus as a risk factor for the increase in incidence of tonsillar cancer. *Int J Cancer*. 2006;119(11):2620–2623.
73. Chaturvedi AK, Engels EA, Pfeiffer RM, et al. Human papillomavirus and rising oropharyngeal cancer incidence in the United States. *J Clin Oncol*. 2011;29(32):4294–4301.
74. Schiller JT, Castellsague X, Garland SM. A review of clinical trials of human papillomavirus prophylactic vaccines. *Vaccine*. 2012;30(suppl 5):F123–F138.
75. Herrero R, Quint W, Hildesheim A, et al. Reduced prevalence of oral human papillomavirus (HPV) 4 years after bivalent HPV vaccination in a randomized clinical trial in Costa Rica. *PLoS One*. 2013;8(7):e68329.
76. Ang KK, Harris J, Wheeler R, et al. Human papillomavirus and survival of patients with oropharyngeal cancer. *N Engl J Med*. 2010;363(1):24–35.
77. Fakhry C, Westra WH, Li S, et al. Improved survival of patients with human papillomavirus-positive head and neck squamous cell carcinoma in a prospective clinical trial. *J Natl Cancer Inst*. 2008;100(4):261–269.
78. Lin BM, Wang H, D'Souza G, et al. Long-term prognosis and risk factors among patients with HPV-associated oropharyngeal squamous cell carcinoma. *Cancer*. 2013 epub ahead of print.
79. Licitra L, Perrone F, Bossi P, et al. High-risk human papillomavirus affects prognosis in patients with surgically treated oropharyngeal squamous cell carcinoma. *J Clin Oncol*. 2006;24(36):5630–5636.
80. Hong AM, Martin A, Armstrong BK, et al. Human papillomavirus modifies the prognostic significance of T stage and possibly N stage in tonsillar cancer. *Ann Oncol*. 2013;24(1):215–219.
81. Herfs M, Yamamoto Y, Laury A, et al. A discrete population of squamocolumnar junction cells implicated in the pathogenesis of cervical cancer. *Proc Natl Acad Sci U S A*. 2012;109(26):10516–10521.
82. Rampias T, Sasaki C, Psyrri A. Molecular mechanisms of HPV induced carcinogenesis in head and neck. *Oral Oncol*. 2013 epub ahead of print.