

# Mosaic double aneuploidy: Down syndrome and XYY

Mayur Parihar<sup>1</sup>, Beena Koshy<sup>2</sup>, Vivi Miriam Srivastava<sup>1</sup>

<sup>1</sup>Cytogenetics Unit, <sup>2</sup>Developmental Paediatrics, Christian Medical College, Vellore, Tamil Nadu, India

Chromosomal abnormalities are seen in nearly 1% of live born infants. We report a 5-year-old boy with the clinical features of Down syndrome, which is the most common human aneuploidy. Cytogenetic analysis showed a mosaicism for a double aneuploidy, Down syndrome and XYY. The karyotype was 47, XY,+21[19]/48, XYY,+21[6]. *ish* XYY (DXZ1 × 1, DYZ1 × 2). Mosaic double aneuploidies are very rare and features of only one of the aneuploidies may predominate in childhood. Cytogenetic analysis is recommended even if the typical features of a recognized aneuploidy are present so that any associated abnormality may be detected. This will enable early intervention to provide the adequate supportive care and management.

**Key words:** Disorder of sexual development, double aneuploidy, Down syndrome with XYY, meiotic non-disjunction, mosaic

## Introduction

Down syndrome (trisomy 21) is the most common aneuploidy seen in live born infants. Rarely, infants with typical phenotypic features of Down syndrome may have an additional aneuploidy. We report a patient with Down syndrome who had mosaicism for XYY. There is only one other report of such a patient.<sup>[1]</sup>

## Case Report

Patient was a 17-month-old boy with growth

retardation and developmental delay, the third child of non-consanguineous parents. The father was 37-year-old and the mother was 31-year-old at conception. The antenatal period was uneventful. The child weighed 2.2 kg at birth. The two older siblings were normal and there was no significant family history.

Clinical examination revealed an interactive and social child. His height at admission was 76 cm and weight, 8.65 kg, which were within the normal limits for Down syndrome charts. The phenotype was consistent with Down syndrome with flat facies, hypertelorism, mongoloid slant of the eyes, epicanthal folds and flat nasal bridge, low-set posteriorly placed ears, small abnormal pinnae, short neck and increased sandal gap. Vision and hearing screening tests were normal. He had hypotonia with exaggerated deep tendon reflexes, hyperextensible elbows, knees and fingers and a flexible calcaneovalgus deformity. He was able to sit with support, grasp objects, recognize parents and vocalize. Neurodevelopmental assessment revealed a developmental age of 7 months. There were no other significant physical findings. Blood investigations including thyroid screening were normal.

Conventional cytogenetic analysis of phytohemagglutinin-stimulated peripheral blood showed trisomy 21 in all 25 metaphases. Six metaphases showed double aneuploidy with an associated XYY [Figure 1], which was confirmed by fluorescence *in situ* hybridization (FISH) analysis [Figure 2] using the centromeric probes for chromosomes X and Y (Abott Molecular, Abbott Park, IL, USA). The karyotype of the child was 47, XY,+21[19]/48, XYY,+21[6]; *in situ* hybridization XYY (DXZ1 × 1, DYZ1 × 2). Parental karyotypes were not available.

Access this article online	
Quick Response Code:	Website: www.ijhg.com
	DOI: 10.4103/0971-6866.120825

**Address for correspondence:** Dr. Vivi Miriam Srivastava, Cytogenetics Unit, Christian Medical College, Vellore - 632 004, Tamil Nadu, India.  
E-mail: cytogen@cmcvellore.ac.in

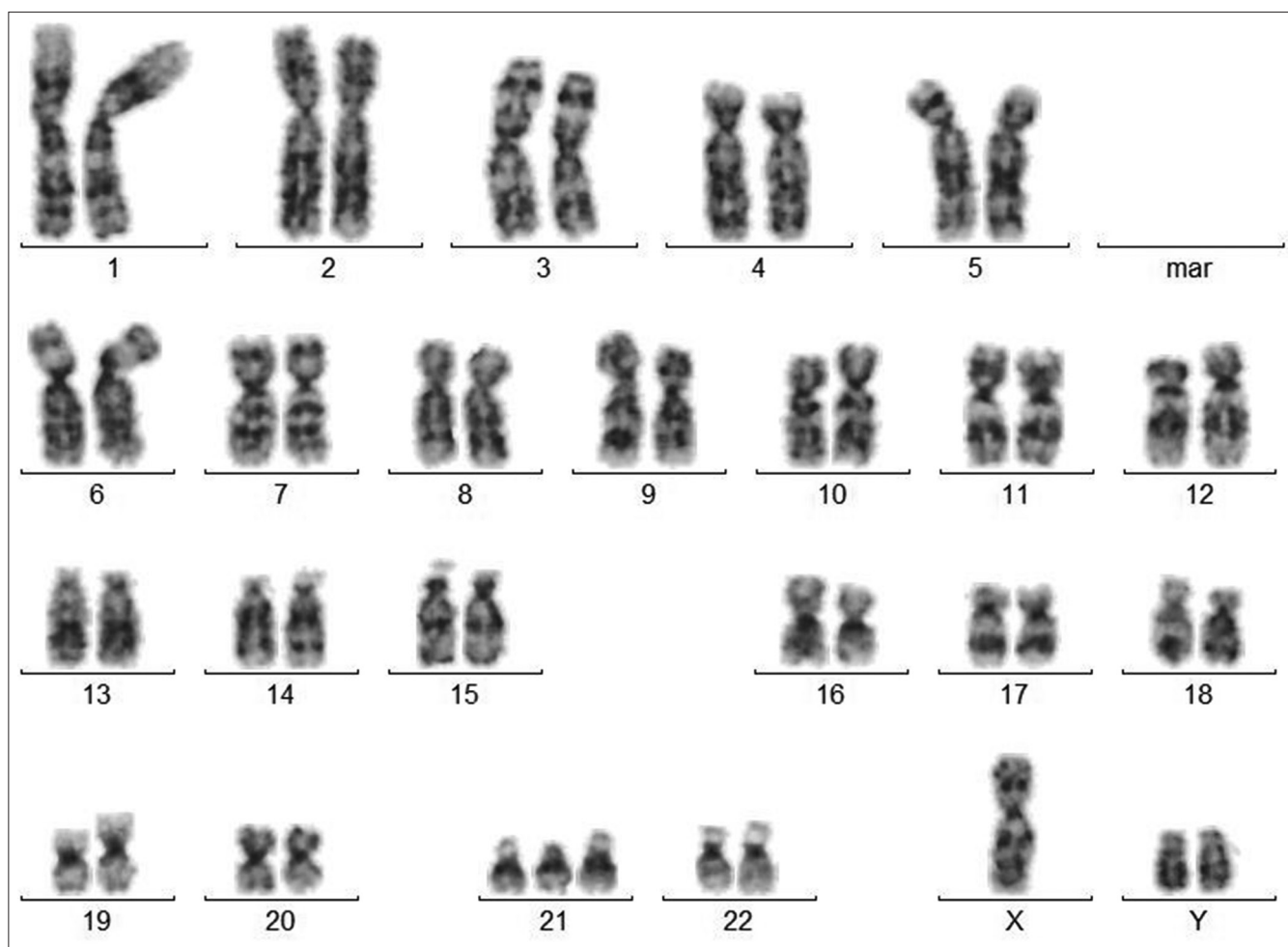


Figure 1: G-banded karyotype showing 48, XYY,+21

## Discussion

Double aneuploidy was first described in a patient with both Down and Klinefelter (48, XXY,+21) syndromes.<sup>[2]</sup> This is also the most commonly described double aneuploidy. Fewer than 40 cases of Down syndrome with XYY have been reported until date,<sup>[3]</sup> only one of which has mosaicism for XYY.

Aneuploidies are due to non-disjunction at meiosis or post zygotic mitosis. Double aneuploidy results when there is non-disjunction involving two chromosome pairs in one or both parents. Non-disjunction during maternal meiosis I is the most common cause of trisomy 21. The XYY occurs when 24YY spermatozoa are formed due to non-disjunction either at paternal meiosis II or mitosis.<sup>[4]</sup> Unlike Down syndrome, the XYY is not associated with increased parental age.

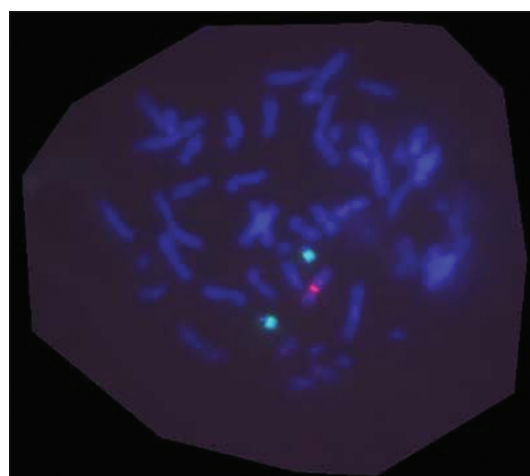


Figure 2: Fluorescence *in situ* hybridization analysis with centromeric probes for chromosomes X (red) and Y (green) showing XYY

The presence of an associated sex chromosome abnormality in children with Down syndrome may not be clinically evident until puberty. The only consistent

phenotypic feature associated with the XYY syndrome is tall stature, which becomes evident at about 5-6 years of age. These children may have learning difficulties, attention deficits, hyperactivity and increased aggressiveness. However, the behavioral changes appear to be variable and may be modified by the environment in which these children live.<sup>[5]</sup> Therefore, it is important to recognize the XYY abnormality at the earliest so that these children can be evaluated periodically and given appropriate care and interventions for learning and behavioral needs.

This report re-emphasizes the need for cytogenetic analysis in young children with Down syndrome even if the phenotype is typical, so that any associated abnormality may be detected. The developmental, cognitive and behavioral profile of children with sex chromosome aneuploidy differs from trisomy 21 and warrants regular follow-up and interventions to optimize the developmental potential of the child. Early detection therefore has a significant role in modifying outcome.

## References

1. Schwanitz G, Hagner M. Double trisomy as a mosaic. Case history (48, XYY, +21/47, XY, +21) and survey of the literature of mixed autosomal-gonosomal trisomies. *Acta Genet Med Gemellol (Roma)* 1978;27:67-74.
2. Ford CE, Jones KW, Miller OJ, Mittwoch U, Penrose LS, Ridler M, *et al.* The chromosomes in a patient showing both mongolism and the Klinefelter syndrome. *Lancet* 1959;1:709-10.
3. Borgaonkar DS. *Chromosomal Variation in Man: A Catalog of Chromosomal Variants and Anomalies*. 8th ed. published by Wiley-Liss, Inc., New York, 1997. Available from: <http://www.wiley.com/legacy/products/subject/life/borgaonkar/access.html>. [Last Accessed on 2011 Mar 10].
4. Robinson DO, Jacobs PA. The origin of the extra Y chromosome in males with a 47, XYY karyotype. *Hum Mol Genet* 1999;8:2205-9.
5. Schiavi RC, Theilgaard A, Owen DR, White D. Sex chromosome anomalies, hormones, and aggressivity. *Arch Gen Psychiatry* 1984;41:93-9.

**Cite this article as:** Parihar M, Koshy B, Srivastava VM. Mosaic double aneuploidy: Down syndrome and XYY. *Indian J Hum Genet* 2013;19:346-8.

**Source of Support:** Nil, **Conflict of Interest:** None declared.

