

# Three-dimensional Imaging in orthodontics

Falguni Mehta, Vijay Vaghela

Department of Orthodontics, Government Dental College and Hospital, Ahmedabad, Gujarat, India

## ABSTRACT

Accurate patient's record and reliable information are keys to our understanding of orthodontics. The development of integrated three-dimensional tools for diagnosis and treatment planning is one of the most exciting developments in orthodontics as the specialty moves into the 21<sup>st</sup> century. Three-dimensional imaging techniques provide extensive possibilities for the detailed and precise analysis of the whole craniofacial complex, for virtual (on-screen) simulation and real simulation of orthognathic surgery cases on biomodels before treatment, as well as for the detailed evaluation of the effects of treatment.

**Key words:** Stereophotogrammetry, three-dimensional imaging, virtual orthodontic patient

## Introduction

Images of the craniofacial region are an important component of orthodontic patient record. The gold standard that orthodontic record attempt to achieve is the accurate replication or portrayal of the "anatomic truth." The anatomic truth is the accurate three-dimensional anatomy static in the function, as it exists *in vivo*. Many technologies, including imaging, articulators, jaw tracking and functional analysis are included in orthodontic record to delineate the anatomic truth. Three-dimensional diagnosis is the most common tool that the orthodontist used to measure and record the size and form of craniofacial structures.

Three-dimensional cephalometry is a powerful tool for planning, monitoring, and evaluation of craniofacial morphology and growth. It allows objective immediate and long-term postoperative assessment of virtual planned or assisted craniofacial surgical procedures. The accuracy and reliability of three-dimensional cephalometry, however, depends on the correct application of the method.<sup>[1]</sup>

## Historical Review

The earliest three-dimensional measurements of the skull were made by anatomists and physical anthropologists in the late 19<sup>th</sup> century. The reference planes of Frankfort, His and Camper, and most of the skeletal landmarks we now use were defined and measured directly on dried skulls before 1900.

Among the earliest systems of measuring the spatial relationships between the teeth and the skull in living subjects, were Van Loon and Simon. Simon's apparatus included a maxillary clutch and frame that resembled and foreshadowed the later face bows of Hanau, McCollum, and all their modern variants.

By 1925, X-ray cephalometry had become feasible, and the stage was set for the classic work of Broadbent<sup>[2]</sup> [Figure 1].

In the 1960s and 1970s, a number of investigators sought to implement the use of stereophotogrammetric methods, originally developed for aerial mapping to measure the skull and other anatomical systems.

In the late 1970s, computerized axial tomography (CAT) (first referred to as CAT and later as computed tomography [CT]) became available. For a brief period it was thought by many that CT and the magnetic resonance imaging (MRI) modality that followed soon afterward (first referred to as nuclear magnetic resonance and later as MRI) would replace conventional projection radiology.

### Access this article online

#### Quick Response Code:



**Website:**  
www.jorthodrr.org

**DOI:**  
10.4103/2321-3825.158135

**Address for correspondence:** Dr. Vijay K. Vaghela, 1 Shivam Tenament, Near I.P. School, Chandkheda, Ahmedabad, Gujarat - 382 424, India. E-mail: v.k.vaghela@gmail.com

Very recently (1998), at least one new CT-like system that uses a different optimization strategy and is specialized for craniofacial applications has made an appearance and based on cone beam (CB) technique.<sup>[3-9]</sup>

## Basic Principles of Three-Dimensional Imaging

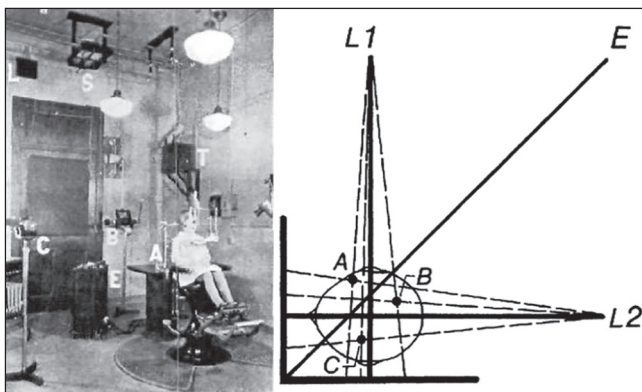
### General Three-Dimensional Concepts

Before exploring the different techniques available, it is necessary to understand some of the principles and terminology in three-dimensional imaging. In two-dimensional photographs or radiographs, there are two axes (the vertical and the horizontal axes), while the Cartesian coordinates system in three-dimensional images consists of the x-axis (or the transverse dimension), y-axis (or the vertical dimension), and the z-axis (the anteroposterior dimension “depth axis”).

Figure illustrates the right-handed xyz coordinate system, which is used in three-dimensional medical imaging. The x-, y- and z-coordinates define a space in which multidimensional data are represented, and this space is called the three-dimensional space [Figure 2].

Three-dimensional models are generated in several steps. The first step:

1. “Modeling,”<sup>[10,11]</sup> uses mathematics to describe the physical properties of an object. The modeled object can be seen as a “wireframe” (or a “polygonal mesh”). The second step is to add some shading and lighting, which brings more realism to the three-dimensional object.
2. The final step is called “rendering,” in which the computer converts the anatomical data collected from the patient into a life-like three-dimensional object viewed on a computer screen.



**Figure 1:** The original broadbent cephalometer. The frontal cephalogram is generated from the position L2 while the lateral cephalogram is generated from a position L1

Udupa and Herman<sup>[12]</sup> classified three-dimensional imaging approaches into three categories:

- Slice imaging, e.g., a set of CT axial data to produce reconstructed two-dimensional images.
- Projective imaging, e.g., surface laser scanning to produce what is considered a 2.5-D mode of visualization.
- Volume imaging, e.g., holography or “varifocal mirrors” techniques.

Projective imaging is the most popular three-dimensional imaging approach, but it does not provide a true three-dimensional mode of visualization similar to what is offered by the volume imaging approach.<sup>[12]</sup>

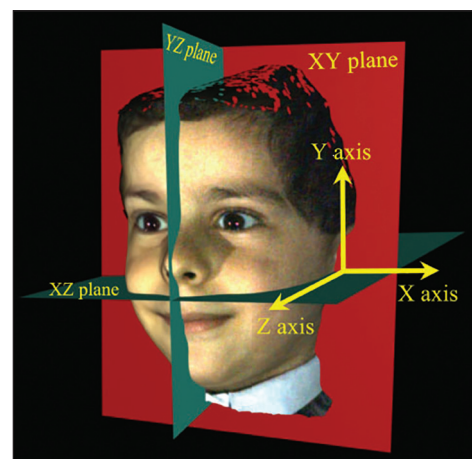
### Three-Dimensional Measurements

There are two main geometrical strategies for measuring in three-dimensional. They are:

1. Orthogonal measurement and
2. Measurement by triangulation.

## Methods of Three-Dimensional Facial Imaging

Orthodontic treatment is aimed at affecting the craniofacial relationships in three planes of space. Yet strangely enough, the critical diagnostic records are two-dimensional. In an orthodontic setting, the techniques of imaging the human face in a three-dimensional manner have been either stereo photography or projection of optical grids or the structured light. These projections enable the operator to capture the facial image in a three-dimensional manner. Unfortunately, all these methods are static in nature. The laser scanning techniques and the availability of sophisticated software for image manipulation, make image animation possible.<sup>[4,8,9]</sup>



**Figure 2:** Right-handed xyz coordinates system

## Grid Projection Techniques

- Moiré topography.
- Structured light.
- Laser scanners.
- Stereophotogrammetry.
- Three-dimensional facial morphometry.

## Methods of Three-Dimensional Craniofacial Skeletal Imaging

- Computed tomography scans.
- Tomosynthesis and Tuned Aperture CT.

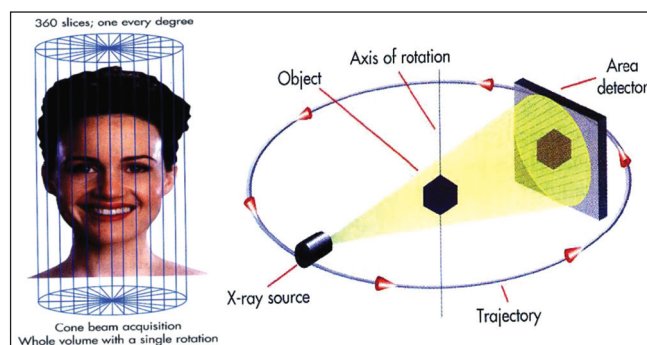
## Cone Beam Computed Tomography

These devices are based on conventional CT technology along with a number of enhancements to optimize them for imaging the head and neck. A reduced chamber volume, small enough for just the head and neck, in itself, allows for a significant reduction in radiation exposure. Real-time feedback between the digital sensor and X-ray source allow for increases or reductions in X-ray energy to account for variations in patient size and tissue density as the patient is being imaged, to provide optimal images while further reducing radiation exposure.

The manufacturer reports a precision of 0.28 mm, which is approximately a 5-10-fold improvement on conventional CT. Speed of image acquisition is also greatly improved. The patient's head is in the imaging chamber for a just over 1 min of which only 18 s is the exposure time<sup>[8,9]</sup> [Figures 3 and 4].

## Cone Beam Computed Tomography Advantages

Because cone-beam computed tomography (CBCT) provides images of high contrasting structures well, it is well-suited for evaluating calcified structures such as bone and teeth. Combined with the limitation of field of view (FOV), CBCT is almost perfectly positioned for dentistry in general and orthodontic assessment in particular.

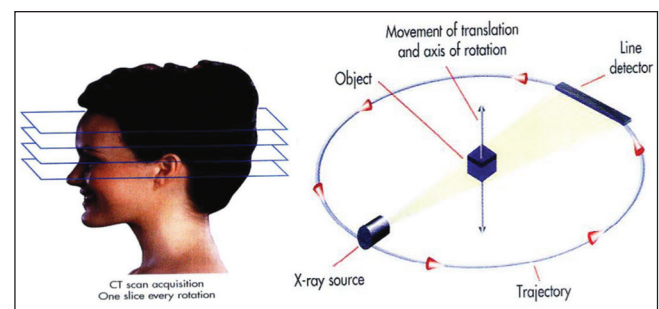


**Figure 3:** Cone beam computed tomography

- Variable FOV - Collimation of the CBCT primary radiograph beam, if available, enables limitation of X-radiation exposure to the region of interest.
- Submillimeter resolution - CBCT units use megapixel solid state devices for X-ray detection providing a minimal voxel resolution of between 0.07 mm and 0.25 mm isotropically, exceeding most high-grade multislice CT capabilities in terms of spatial resolution.
- High-speed scanning - CBCT systems can sometimes scan an entire head in 10 s or less, which is shorter than the typical panoramic radiology sequence.
- Dose reduction - reports indicate that CBCT patient absorbed dose is reported to be significantly reduced when compared with conventional CT.
- Voxel isotropy.
- Real-time analysis and enhancement.
- Three-dimensional representation of dental and craniofacial structures.
- Custom image reformatting to provide optimal visualization from different angles and perspectives.
- Orthogonal images that do not contain magnification errors or projection artifacts.
- Management of superimpositions.
- Interoperability in Digital Imaging and Communications in Medicine format.
- Generation of data that can be used in other diagnostic, modeling, and manufacturing applications; and
- Radiation exposure within a similar range of other dental radiographic imaging devices, but of a magnitude lower than that of medical CT devices.<sup>[12-16]</sup>

There are numerous CBCT systems currently on the market, with an estimate of > 30 CBCT device manufacturers worldwide as of early 2009. Configurations vary from system to system, with differences in:

1. Patient position during image acquisition (supine position similar to medical CT devices, stand-up configurations patterned after common panoramic machines, seated units, or portable systems developed for intraoperative examination and mobile scanning centers),
2. Image capture sensor type,



**Figure 4:** Conventional computed tomography

3. FOV, (4) X-ray generator, and (5) reconstruction algorithm and visualization software.

There are currently four main system providers in the world market:

- NewTom 3G (Quantitative Radiology, Verona, Italy).
- i-CAT (Imaging Sciences International, Hatfield, USA).
- CB Mercuray (Hitachi Medical Corporation, Tokyo, Japan).
- Three-dimensional Accuitomo (J Morita Mfg Corp, Kyoto, Japan).

The NewTom was the first device in the dental market to use CBCT technology.

Important uses of CBCT volume<sup>[14-17]</sup> for orthodontic diagnosis and treatment planning, includes the following:

- Lateral and frontal cephalometric views.
- Three-dimensional skeletal views and a three-dimensional review of the dentition.
- Alveolar ridge shape and volume.
- Temporomandibular joints (TMJ).
- Sinuses and airway.
- Facial analysis.
- Cleft lip and palate; and
- Facial modeling and therapeutic applications.
- Digital Study Models.

## Radiation Doses from Cone Beam Computed Tomography

**Table 1: Effective doses from common examinations**

Examination	Effective dose (Sv)
F-speed film or PSP with rectangular collimation (full mouth)	35
F-speed film or PSP with a round collimation (full mouth)	171
D-speed film round collimation (full mouth)	388
Lateral cephalometric	5
PA cephalometric	5
Panoramic	9-26
NewTom 3G CBCT55	68
i-CAT extended scan	235
CB Mercuray CBCT	569

CBCT: Cone beam computed tomography, CB: Cone beam, PA: Postero-anterior, PSP: Photostimulable phosphor

## Limitations of cone beam computed tomography<sup>[18]</sup>

Cone beam imaging has limitations for use in orthodontics. These include:

- Supine positioning of the patient during scanning with some machines may alter the position of the facial soft tissues. However, this is the preferred orientation for evaluating for sleep apnea.

- There may be difficulty in identifying anatomic landmarks with some CB units due to lack of fine detail or ambiguities in the definition of landmarks including sella, porion, and articulare.
- Metal artifacts from dental restorations and implants compromise image quality in the occlusal plane although some success has been reported in reducing this problem.
- Radiation exposure is best measured as effective dose. The effective dose from conventional panoramic and cephalometric views is much less than from CB examinations.

## Applications of Three-Dimensional Imaging of the Teeth<sup>[19-22]</sup>

- Three-dimensional images are a reliable way to archive study models, producing durable images without any fear of loss or damage to the original casts. If a model requires 5 Mb of space, one CD-ROM can accommodate between 130 and 145 study casts. A hard disc of a 60-Gb capacity can accommodate approximately 12,000 study models.<sup>[23]</sup>
- Documentation of treatment progress and communication between professional colleagues is also made easier by examining records in three-dimensional.<sup>[24]</sup>
- With new advances in three-dimensional dental and orthodontic software, the orthodontist can examine intra- and inter-arch relationships with much more precision. Transverse relationships between upper and lower arches could be better evaluated when three-dimensional models are viewed in occlusion from different angles on the screen. Treatment objectives and treatment planning can be created taking into account the different treatment options, ending with what could be termed “virtual treatment” and “virtual set-up” of the orthodontic appliance.<sup>[25]</sup>
- Simulation of space closure following extraction, tooth uprighting or incisor retraction can be easily shown to patients, which increases their understanding and perhaps, their compliance.<sup>[26]</sup>
- Three-dimensional prefabrication of archwires using specific robotics after setting up bracket positions on the dental arches.
- Construction of three-dimensional “aligners,” which are thin, clear, overlay appliances used in a sequential manner over a period of time to correct a malocclusion without the need for conventional fixed appliances (The Invisalign® technology).

## Virtual Orthodontic Patient

The ultimate dream of three-dimensional imaging and modeling is to achieve the “virtual orthodontic patient,” where we can see the bone, flesh and teeth in three-dimensional. If this can be achieved in an accurate way, it will allow considerable data to be collected and a variety of soft and hard tissue analyses to be performed. Our knowledge of the masticatory system will increase, and our understanding of tooth movement biomechanics, orthopedic and orthognathic corrections will be enhanced.<sup>[23,24,27-29]</sup>

## Orthocad™ Technology

OrthoCAD™ software has been developed by CADENT, Inc., (Computer Aided DENTistry, Fairview, NJ, USA) to enable the orthodontist to view, manipulate, measure, and analyze three-dimensional digital study models easily and quickly [Figure]. Alginate impressions of the maxillary and mandibular dentitions, together with a bite registration are required for the construction of three-dimensional digital study models, which are then downloaded manually or automatically from the worldwide website using a utility called OrthoCAD downloader. The average file size for each three-dimensional model is 3 Mb.

The software comes with several diagnostic tools such as: Measurement analyses (e.g., Bolton analysis, arch width, and length analyses); midline analysis, “Occlusogram,” etc.

Recently, the utility has been added to the software, “OrthoCAD virtual set-up,” which is based on the straight wire philosophy. OrthoCAD™ Bracket Placement System is another addition to the system.<sup>[18,19,21]</sup>

## Align® Technology

Align® Technology, Inc., developed the invisalign appliance for orthodontic tooth movement in the USA in 1998. It is an “invisible” way to straighten teeth into a perfect occlusion using thin, clear, overlay sequential appliances. The invisalign process begins with the orthodontist making an initial diagnosis and mapping out a course of treatment. Then these are sent to Align® Technology, together with the patient’s radiographs, impressions of the patient’s teeth and an occlusal registration.

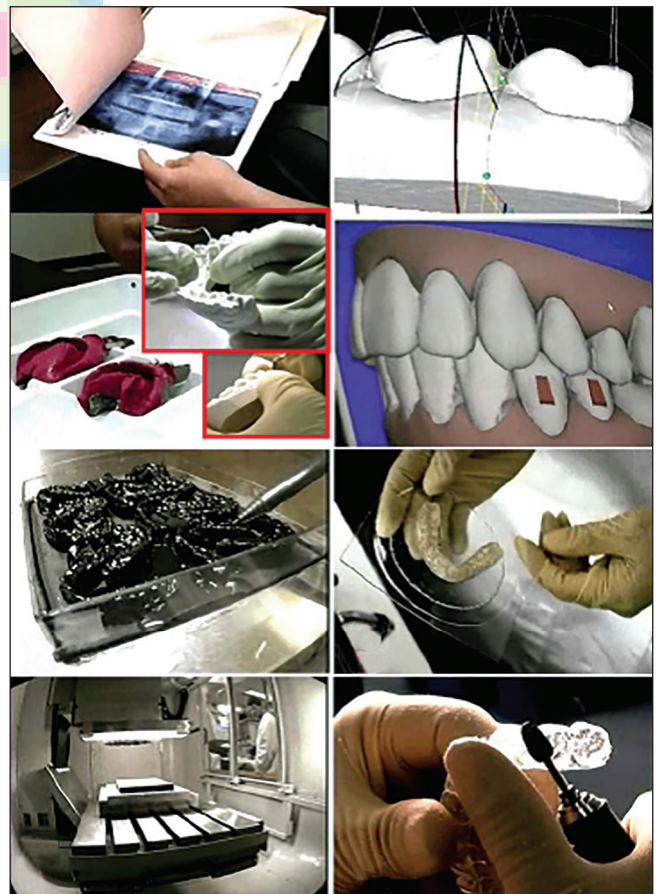The treatment is divided into a series of stages that go from the current condition to the desired end result. This simulation is then electronically delivered to the orthodontist for final quality approval, following which a series of dental models are constructed

from photosensitive thermoplastic. These are used to fabricate the finished product: A series of clear invisalign aligners.

The patient is instructed to wear each aligner for approximately 1-2 weeks, and then to move forward to the next stage. The first university-based clinical study reported successful clinical results of subjects with varying degrees of mild to moderate malocclusion treated by this means. Although, the manufacturing company claims that the appliance can be used to treat Class II and III sagittal discrepancies, as well as vertical and transverse discrepancies, more clinical studies need to be conducted to prove or disapprove such claims [Figure 5].<sup>[30-32]</sup>

## Magnetic Resonance Imaging Scanning and Orthodontics

The use of MRI within the dental and maxillofacial profession continues to evolve. The use of MRI in orthodontics is low, but it has been used to image the TMJ during functional appliance treatment orthodontists



**Figure 5:** Invisalign

should have an understanding of MRI techniques in order to understand how orthodontic appliances *in situ* may affect the diagnostic quality of these scans. In addition, the orthodontist should be aware of the procedures to be followed, should a patient wearing fixed orthodontic appliances require an MRI scan.<sup>[31,33-37]</sup>

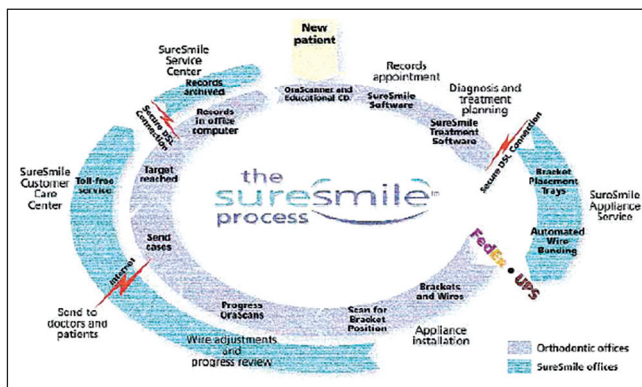
## SureSmile

The SureSmile (OraMetrix, Dallas, Tex) process begins with a direct three-dimensional scan of the patient's dentition using the OraScanner (OraMetrix), a light-based imaging device that projects a precisely patterned grid onto the teeth. As the handheld scanner is passed over the dentition, reflected images of the distorted grid are recorded with a video camera built into the handle of the scanner. The scanner is passed over the teeth in a rocking motion to allow visualization of all tooth surfaces, including undercut areas. The process takes approximately a minute and a half per arch. During this time, multiple and overlapping images go to the computer. With sophisticated data registration and management techniques, the images are processed, and a computer model of the dentition is produced in real time. The operator assists in identifying the teeth. They are then compared with teeth in a library of dental morphology. Information voids in the scan are filled with data from the library to further refine the model. Once this process is completed, the teeth can be moved like independent objects in three-dimensional with the software controls [Figure 6].<sup>[6,38]</sup>

## Methods of Capturing Mandibular Motion in Three-Dimensional

### Ultrasonic Motion Capture

These systems allow for recording of mandibular movements in real time, recording and display of the three-dimensional movements in digital form.



**Figure 6:** The oramatrix SureSmile process

Following, the parameters of functional analysis, in addition to the settings of a fully adjustable articulator (hinge axis, condylar inclination, and immediate-side-shifts) are calculated and issued in a graphic report. The system is based upon the transmission time measurement of ultrasound impulses with highly sensitive sensors located on the head frame secured to the patient's head [Figure 6].<sup>[39,40]</sup>

## Benefits of Three-Dimensional

1. Diagnosis.
2. Treatment planning, simulation, and therapeutics.
3. Development of future technologies and approaches to orthodontics; and
4. Research-treatment outcomes, evidence-based orthodontics.

## References

1. Grayson B, Cutting C, Bookstein FL, Kim H, McCarthy JG. The three-dimensional cephalogram: Theory, technique, and clinical application. *Am J Orthod Dentofacial Orthop* 1988;94:327-37.
2. Broadbent BH. A new X-ray technique and its application to orthodontics. *Angle Orthod* 1931;1:45-66.
3. White SC, Pharoah MJ. *Oral Radiology Principles and Interpretation*. St Louis: Mosby; 2000.
4. Weeden JC, Trotman CA, Faraway JJ. Three dimensional analysis of facial movement in normal adults: Influence of sex and facial shape. *Angle Orthod* 2001;71:132-40.
5. Moore W. Successful Panoramic Radiography. Kodak Dental Radiography Series. Available from: <http://www.kodak.com/global/en/health/dental/Publications/proedDental.html>; 2001. [Last accessed on 2014 July].
6. Mah J, Sachdeva R. Computer-assisted orthodontic treatment: The SureSmile process. *Am J Orthod Dentofacial Orthop* 2001;120:85-7.
7. Mah J, Enciso R, Jorgensen M. Management of impacted cuspids using 3-D volumetric imaging. *J Calif Dent Assoc* 2003;31:835-41.
8. Mah J, Hatcher D. Current status and future needs in craniofacial imaging. *Orthod Craniofac Res* 2003;6 Suppl 1:10-6.
9. Sukovic P. Cone beam computed tomography in craniofacial imaging. *Orthod Craniofac Res* 2003;6 Suppl 1:31-6.
10. Santoro M, Galkin S, Teredesai M, Nicolay OF, Cangialosi TJ. Comparison of measurements made on digital and plaster models. *Am J Orthod Dentofacial Orthop* 2003;124:101-5.
11. Quimby ML, Vig KW, Rashid RG, Firestone AR. The accuracy and reliability of measurements made on computer-based digital models. *Angle Orthod* 2004;74:298-303.
12. Udupa J, Herman G. eds., *Imaging in Medicine*. Boca Raton, Florida: CRC Press, 1991.
13. Chaushu S, Chaushu G, Becker A. The role of digital volume tomography in the imaging of impacted teeth. *World J Orthod* 2004;5:120-32.

14. Hilgers ML, Scarfe WC, Scheetz JP, Farman AG. Accuracy of linear temporomandibular joint measurements with cone beam computed tomography and digital cephalometric radiography. *Am J Orthod Dentofacial Orthop* 2005;128:803-11.
15. Walker L, Enciso R, Mah J. Three-dimensional localization of maxillary canines with cone-beam computed tomography. *Am J Orthod Dentofacial Orthop* 2005;128:418-23.
16. Halazonetis DJ. From 2-dimensional cephalograms to 3-dimensional computed tomography scans. *Am J Orthod Dentofacial Orthop* 2005;127:627-37.
17. Mah J, Hatcher DC. Craniofacial imaging in orthodontics. In: Graber TM, Vanarsdall RL, Vig KW, editors. *Orthodontics: Current Principles and Techniques*. St Louis: Elsevier; 2005. p. 71-100.
18. Lagravère MO, Major PW. Proposed reference point for 3-dimensional cephalometric analysis with cone-beam computerized tomography. *Am J Orthod Dentofacial Orthop* 2005;128:657-60.
19. Huang J, Bumann A, Mah J. Three-dimensional radiographic analysis in orthodontics. *J Clin Orthod* 2005;39:421-8.
20. Bjerklin K, Ericson S. How a computerized tomography examination changed the treatment plans of 80 children with retained and ectopically positioned maxillary canines. *Angle Orthod* 2006;76:43-51.
21. Cevdanes LH, Styner MA, Proffit WR. Image analysis and superimposition of 3-dimensional cone-beam computed tomography models. *Am J Orthod Dentofacial Orthop* 2006;129:611-8.
22. Moss JP. The use of three-dimensional imaging in orthodontics. *Eur J Orthod* 2006;28:416-25.
23. Swennen GR, Schutyser F. Three-dimensional cephalometry: Spiral multi-slice vs cone-beam computed tomography. *Am J Orthod Dentofacial Orthop* 2006;130:410-6.
24. Patel A, Bhavra GS, O'Neill JR. MRI scanning and orthodontics. *J Orthod* 2006;33:246-9.
25. Ackerman JL, Proffit WR, Sarver DM, Ackerman MB, Kean MR. Pitch, roll, and yaw: Describing the spatial orientation of dentofacial traits. *Am J Orthod Dentofacial Orthop* 2007;131:305-10.
26. Peck JL, Sameshima GT, Miller A, Worth P, Hatcher DC. Mesiodistal root angulation using panoramic and cone beam CT. *Angle Orthod* 2007;77:206-13.
27. Cha JY, Mah J, Sinclair P. Incidental findings in the maxillofacial area with 3-dimensional cone-beam imaging. *Am J Orthod Dentofacial Orthop* 2007;132:7-14.
28. Kumar V, Ludlow J, Soares Cevdanes LH, Mol A. *In vivo* comparison of conventional and cone beam CT synthesized cephalograms. *Angle Orthod* 2008;78:873-9.
29. Turpin DL. British Orthodontic Society revises guidelines for clinical radiography. *Am J Orthod Dentofacial Orthop* 2008;134:597-8.
30. Silva MA, Wolf U, Heinicke F, Bumann A, Visser H, Hirsch E. Cone-beam computed tomography for routine orthodontic treatment planning: A radiation dose evaluation. *Am J Orthod Dentofacial Orthop* 2008;133:640.e1-5.
31. Aboudara C, Nielsen I, Huang JC, Maki K, Miller AJ, Hatcher D. Comparison of airway space with conventional lateral headfilms and 3-dimensional reconstruction from cone-beam computed tomography. *Am J Orthod Dentofacial Orthop* 2009;135:468-79.
32. Baumgaertel S, Palomo JM, Palomo L, Hans MG. Reliability and accuracy of cone-beam computed tomography dental measurements. *Am J Orthod Dentofacial Orthop* 2009;136:19-25.
33. Toma AM, Zhurov A, Playle R, Ong E, Richmond S. Reproducibility of facial soft tissue landmarks on 3D laser-scanned facial images. *Orthod Craniofac Res* 2009;12:33-42.
34. Farman AG, Scarfe WC. The basics of maxillofacial cone beam computed tomography. *Semin Orthod* 2009;15:2-13.
35. Friedland B. Medicolegal issues related to cone beam CT. *Semin Orthod* 2009;15:77-84.
36. White SC, Pae EK. Patient image selection criteria for cone beam computed tomography imaging. *Semin Orthod* 2009;15:19-28.
37. Lenza MG, Lenza MM, Dalstra M, Melsen B, Cattaneo PM. An analysis of different approaches to the assessment of upper airway morphology: A CBCT study. *Orthod Craniofac Res* 2010;13:96-105.
38. Mah JK, Alexandroni S. Cone-beam computed tomography in the management of impacted canines. *Semin Orthod* 2010;16:199-204.
39. Baumrind S. The road to three-dimensional imaging in orthodontics. *Semin Orthod* 2011;17:2-12.
40. Mah JK, Yi L, Huang RC, Choo HR. Advanced applications of cone beam computed tomography in orthodontics. *Semin Orthod* 2011;17:57-71.

**How to cite this article:** Mehta F, Vaghela V. Three-dimensional Imaging in orthodontics. *J Orthod Res* 2015;3:151-7.

**Source of Support:** Nil. **Conflicts of Interest:** No.