

# Capsule Endoscopy: New Technology, Old Complication

Ashwin Rammohan, R. M. Naidu

Department of General Surgery, Apollo Hospitals, Chennai, India

## INTRODUCTION

Capsule endoscopy allows direct visualization of the entire small bowel in a non-invasive manner and has become the gold standard in evaluating obscure gastrointestinal (GI) bleed which is unidentified by traditional endoscopic techniques.<sup>[1]</sup> Since its conception in 2000, wireless capsule endoscopy has become an established tool for minimally invasive evaluation of the small bowel.<sup>[2]</sup> We have highlighted a complication which every gastroenterologist performing capsule endoscopy must be aware of to avoid unnecessary complications. With its use now being extended to evaluating inflammatory bowel disease wherein patients are more likely to have a stricturing disease, our case report becomes that much more significant.<sup>[3]</sup>

## CASE REPORT

A 65-year-old female presented to the emergency department with two days history progressively worsening abdominal distension and peri-umbilical pain. She also had nausea and vomiting. She had been in hospital a week ago for anemia (hemoglobin 7.4 g/dl, MCV 78 fl) and was evaluated with gastroscopy and colonoscopy which were normal. She was then subjected to capsule endoscopy, the results of which were pending. Her capsule endoscopy was 72 hours prior to her visit to the emergency department.

### Access this article online

#### Quick Response Code:



#### Website:

www.jstcr.org

#### DOI:

10.4103/2006-8808.92801

**Address for correspondence:** Dr. Ashwin Rammohan, Department of General Surgery, Apollo Hospitals, Chennai, India. E-mail: ashwinrammohan@gmail.com

## ABSTRACT

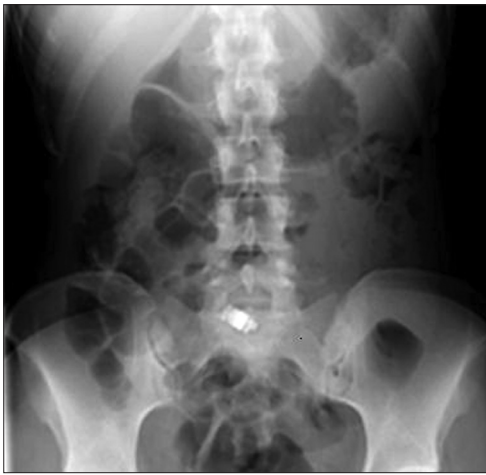Wireless capsule endoscopy is a new tool in the armamentarium of the gastroenterologist to evaluate the small bowel non-invasively. It allows improved diagnostic yield with low complication rates relative to traditional modalities. But this new technology has its own set of complications, some which can lead to significant morbidity. Here, we present a case of complete small bowel obstruction following a capsule endoscopy. A 65-year-old female with a long standing history of anemia and obscure gastrointestinal bleed presented to the Emergency Department 72 hours after a wireless capsule endoscopy procedure complaining of worsening abdominal pain, distension, and frequent vomiting. An X-ray was suggestive of complete distal small bowel obstruction with the capsule at the transition point of dilated proximal and collapsed distal small bowel. The patient was resuscitated and taken up for an explorative laparotomy where a short segment stricture was noted with the capsule endoscope caught proximal to it. The segment was resected and patient made an uneventful recovery. Wireless capsule endoscopy is now becoming the preferred method to image the small bowel. Our report illustrates the importance of appropriate patient selection and evaluation of functional patency of the small bowel may be with a contrast series prior to wireless capsule endoscopy to avoid any post procedural morbidity.

**Key words:** Bowel obstruction, capsule endoscopy, complication

## Physical examination

The patient was in quite a lot of discomfort. Her heart rate was 110 beats/minute, respiratory rate 25/minute, blood pressure 100/70 mmHg, and temperature 37.4°C. Her lungs were clear and heart was regular in rhythm with no murmurs. Abdominal exam revealed a soft but grossly distended abdomen with rebound tenderness over the periumbilical region. She also had percussion tenderness. Rectal examination was normal with soft heme negative stool.

Her blood tests showed a white cell count of 13,300 cells/dl and C-reactive protein (CRP) of 64 mg/dl. X-ray abdominal showed air fluid levels with a distended small bowel and a retained capsule endoscope in the terminal ileum consistent with a small bowel obstruction [Figure 1]. Based on the clinical and X-ray findings, it was decided to take the patient for an explorative laparotomy. Patient was optimized and was taken for surgery. Intraoperatively, a 3 cm segment of

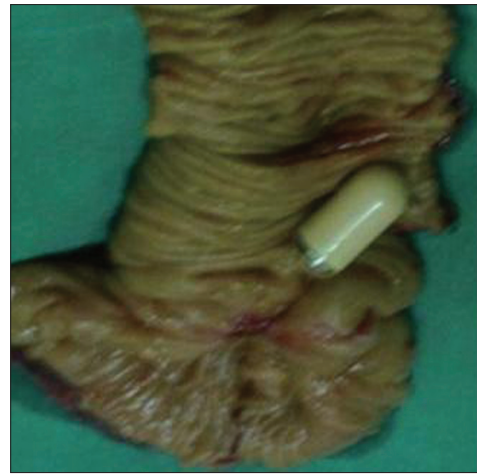

**Figure 1:** X-ray abdomen showing small bowel obstruction

strictured bowel was noted with the capsule endoscope occluding the bowel at the proximal end of the stricture [Figure 2]. The strictured segment along with capsule endoscope was resected and normal appearing distal and proximal bowel were anastomosed. Histopathology of the resected specimen showed inflammatory infiltration of the wall with fibrosis of the muscularis propria, suggestive of non specific chronic inflammation. There was no evidence of granulomata, crypt abscesses, or malignancy. The images from the operatively retrieved capsule endoscope were analyzed; they showed multiple angiodysplastic lesions in the proximal small bowel. The patient's post operative period was uneventful and was discharged on the 8<sup>th</sup> post operative day.

## DISCUSSION

Capsule endoscopy has gained widespread acceptance as an important imaging modality for small bowel pathology. The capsule endoscope consists of an 11 mm × 26 mm ingestible endoscope included in which are a wireless video camera, illumination system, batteries, and an image transmitter. Images are recorded by a sensing system worn on the patient's belt which is removed for image download approximately eight hours after capsule ingestion.<sup>[2]</sup> Seventy-five percent of capsules enter the colon during the eight-hour acquisition time. Subsequently, the disposable plastic-covered capsule is excreted in the stool 10–48 hours later. Indications for capsule endoscopy include obscure gastrointestinal bleeding, suspected inflammatory bowel disease, malabsorptive syndrome, or small intestinal tumors, and surveillance for patients with polyposis syndromes. The list of relative contraindications includes patients with known or suspected GI obstruction, stricture, fistula, or motility disorders, patients with cardiac pacemakers or other implanted electro-medical devices, dysphagia, and pregnancy.<sup>[4]</sup> The incidence of capsule retention



**Figure 2:** Resected specimen of small bowel with capsule endoscope

ranges from 0% to 13% with the most common site of detainment in the ileum, similar to our patient.<sup>[4,5]</sup> Capsule retention occurs frequently in patients with known Crohn's disease.<sup>[6,7]</sup> Capsule retention rarely causes symptoms, but can potentially cause small bowel obstruction or perforation.<sup>[8-12]</sup>

Patients with abdominal pain, distension, and nausea after capsule endoscopy should be evaluated for impaction and small bowel obstruction or perforation. Diagnosis may be aided by interpretation of capsule images.<sup>[8,9]</sup> Abdominal X-rays or CT will typically demonstrate a radio-opaque density in the small bowel with proximal small bowel dilatation. Studies looking at asymptomatic capsule retention has shown that capsule retrieval is not emergent in asymptomatic retainers.<sup>[5,6,8,13]</sup> The longest reported case of capsule retention is 2.5 years.<sup>[13]</sup> Asymptomatic capsule retention may be treated with medical, endoscopic, or surgical intervention.<sup>[6,12,13]</sup>

Non-surgical interventions include enemas and enteroscopy with snare retrieval.<sup>[6,8,12,13]</sup> Surgical interventions may be laparoscopic or more commonly open surgery to recover the capsule via an enterotomy or intraoperative manual bowel manipulation and digital rectal retrieval.<sup>[8,10,12,13]</sup> Surgical intervention helps to remove both the obstructing lesion and the retained capsule.<sup>[6,11,12]</sup>

In the present case, capsule impaction secondary to an asymptomatic stricture in the terminal ileum was likely the inciting mechanism leading to acute small bowel obstruction. Use of more rigorous pre-procedure evaluation should therefore be pursued. Specifically, additional imaging in the form of a barium follow-through and CT enterography may help characterize the small bowel prior to capsule endoscopy, although the presence


or absence of a stricture does not necessarily preclude the possibility of small bowel obstruction.<sup>[6,12]</sup> Our report, in combination with a few others, suggests that more serious complications than previously anticipated exist for this technique.<sup>[4,8,9-13]</sup> Capsule endoscopists must exercise extended caution in patient selection, especially as the utilization of capsule endoscopy increases in the management of inflammatory bowel disease.

## REFERENCES

1. Appleyard M, Glukhovsky A, Swain P. Wireless-capsule diagnostic endoscopy for recurrent small-bowel bleeding. *N Engl J Med* 2001; 344:232-3.
2. Iddan G, Meron G, Glukhovsky A, Swain P. Wireless capsule endoscopy. *Nature* 2000;405:417.
3. Triester SL, Leighton JA, Leontiadis GI, Gurudu SR, Fleischer DE, Hara AK, *et al.* A meta-analysis of the yield of capsule endoscopy compared to other diagnostic modalities in patients with non-stricturing small bowel Crohn's Disease. *Am J Gastroenterol* 2006;101:954-64.
4. Fireman Z, Eliakim R, Adler S, Scapa E. Capsule endoscopy in real life: A 4 center experience of 160 consecutive patients in Israel. *Eur J Gastroenterol Hepatol* 2004;16:927-31.
5. Cave D, Legnani P, de Franchis R, Lewis BS; ICCE. ICCE consensus for capsule retention. *Endoscopy* 2005;37:1065-7.
6. Lin OS, Brandabur JJ, Schembre DB, Soon MS, Kozarek RA. Acute symptomatic small bowel obstruction due to capsule impaction. *Gastrointest Endosc* 2007;65:725-8.
7. Levsky JM, Milikow DL, Rozenblit AM, Wolf EL. Small bowel obstruction due to an impacted endoscopy capsule. *Abdom Imaging* 2008;33:579-81.
8. Um S, Poblete H, Zavotsky J. Small bowel perforation caused by an impacted endocapsule. *Endoscopy* 2008;40 Suppl 2:E122-3.
9. Repici A, Barbon V, De Angelis C, Luigiano C, De Caro G, Hervoso C, *et al.* Acute small-bowel perforation secondary to capsule endoscopy. *Gastrointest Endosc* 2008;67:180-3.
10. Cheon JH, Kim YS, Lee IS, Chang DK, Ryu JK, Lee KJ, *et al.* Can we predict spontaneous capsule passage after retention? A nationwide study to evaluate the incidence and clinical outcomes of capsule retention. *Endoscopy* 2007;39:1046-52.
11. Ikorucu O, Tascilar O, Emre AU, Cakmak GK, Karakaya K, Ucan BH, *et al.* Small-bowel obstruction secondary to a wireless capsule enteroscopy: Extraction of the capsule without enterotomy. *Endoscopy* 2007;39 Suppl 1:E286-7.
12. Karagiannis S, Faiss S, Mavrogiannis C. Capsule retention: A feared complication of wireless capsule endoscopy. *Scand J Gastroenterol* 2009;44:1158-65.
13. Dominguez EP, Choi Y, Rajman IL, Sweeney JF. Laparoscopic approach for the retrieval of retained video capsule endoscopy. *JSLS* 2006;10:496-8.

**How to cite this article:** Rammohan A, Naidu RM. Capsule endoscopy: New technology, old complication. *J Surg Tech Case Report* 2011;3:91-3.

**Source of Support:** No financial ties to disclose, **Conflict of Interest:** No conflicts of interest



## Staying in touch with the journal

### 1) Table of Contents (TOC) email alert

Receive an email alert containing the TOC when a new complete issue of the journal is made available online. To register for TOC alerts go to [www.jstcr.org/signup.asp](http://www.jstcr.org/signup.asp).

### 2) RSS feeds

Really Simple Syndication (RSS) helps you to get alerts on new publication right on your desktop without going to the journal's website. You need a software (e.g. RSSReader, Feed Demon, FeedReader, My Yahoo!, NewsGator and NewzCrawler) to get advantage of this tool. RSS feeds can also be read through FireFox or Microsoft Outlook 2007. Once any of these small (and mostly free) software is installed, add [www.jstcr.org/rssfeed.asp](http://www.jstcr.org/rssfeed.asp) as one of the feeds.