

“The Dendritic Bonding Technique”: A Newly-devised Technique for the Fixation of Mesh Skin Graft

Yoshiaki Sakamoto, Kazuo Kishi

*Department of Plastic and Reconstructive Surgery,
Keio University School of Medicine, 35 Shinanomachi,
Shinjuku-ward, Tokyo, Japan*

INTRODUCTION

Skin grafting is a widely used method for the reconstruction of wound closures that cannot be closed primarily. Skin grafts are indicated to accelerate the healing of burns, ulcers, and other wounds, reduce scar contractures, and enhance cosmesis. A skin graft may be meshed to cover a greater surface area at the recipient site. This meshing also allows for the egress of serous and sanguinous fluids. Surgical staples are a common and expeditious method of affixing a mesh skin graft, particularly to large recipient areas. The sewing of the graft using absorbable sutures may be more prudent in children or sensitive areas of adults. However, these affixing procedures have disadvantages, such as pain during staple removal and the time required for suturing. We developed the “dendritic bonding technique” described below to avoid these problems.

SURGICAL TECHNIQUE

The edges of a meshed skin graft are generally not mesh like but exhibit a dendritic structure. These “dendritics” are sometimes trimmed or placed on normal skin, but they are not merely left to dry and drop off. Dendritics are too small to thread, but they can be attached using octyl-2-cyanoacrylate (Dermabond; Ethicon Inc.,

ABSTRACT

We describe a newly designed technique for the quick, easy, and cost-effective fixation of mesh skin grafts in a range of skin conditions and patients. We fixed the skin graft using octyl-2-cyanoacrylate (Dermabond; Ethicon), which was termed “Dendritic bonding.” This technique exhibits several advantages over surgical stapling and suturing with absorbable sutures.

Key words: Dermabond, mesh, octyl-2-cyanoacrylate, skin graft

Somerville, NJ, USA) at the normal skin edge. The dendritics must be bonded in several places [Figure 1]. However, we do not affix the graft on the recipient’s defective skin area because of the danger of obstructing the epithelialization of the mesh.

The final dressing is performed by bolster dressing. Alternatively, we use negative-pressure dressings (VAC; Kinetic Concepts Inc., San Antonio, TX, USA). A nonadherent material must be placed as an interface between the skin graft and the VAC sponge to prevent a disruption of the graft during removal of the dressing.

The initial dressing should remain in place for approximately 5 days (3-7 days) unless pain, odor, discharge, or other signs of complication develop.

RESULTS

A total of 14 patients (five males and nine females) underwent skin graft using this technique. The ages ranged from 9 months to 86 years (mean = 62.3 years). The skin defects included two burn ulcers, two decubitus, and 10 chronic leg ulcers. The size of the defects ranged from 20 cm² to 210 cm². All grafts were accepted without complications.

A 72-year-old man with a chronic leg ulcer after debridement for necrotizing fasciitis is presented as a representative case [Figures 2 and 3].

DISCUSSION

Dermabond is a well-established tool for wound closure.

Access this article online

Quick Response Code:



Website:

www.jstcr.org

DOI:

10.4103/2006-8808.110258

Address for correspondence: Dr. Yoshiaki Sakamoto,
Department of Plastic and Reconstructive Surgery,
Keio University School of Medicine, 35 Shinanomachi,
Shinjuku-ward, Tokyo 160 - 8582, Japan.
E-mail: ysakamoto@z8.keio.jp

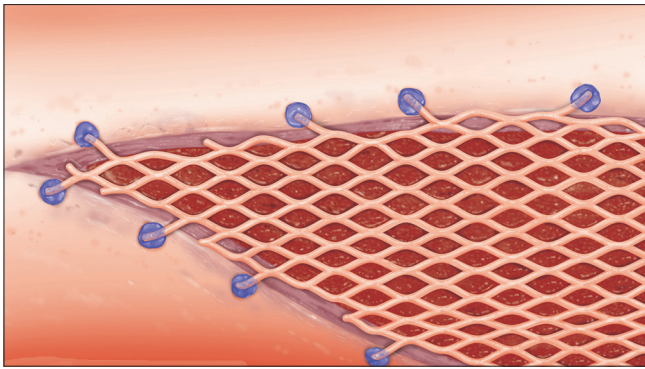


Figure 1: Illustration of the technique

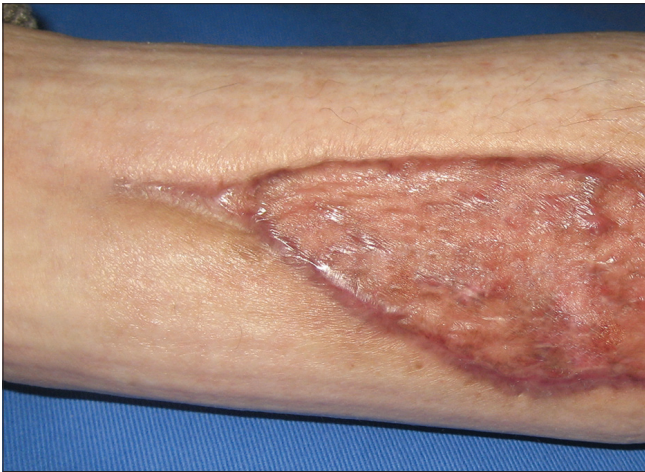

Figure 3: Six-month postoperative result

Dermabond was initially used to replace the suturing of superficial wounds, but it is currently used in a variety of techniques.^[1] Dermabond has been used recently as a skin bolster to assist the primary closure of wounds in patients with thin skin.^[2]

We used Dermabond for the pasting of meshed skin grafts. This technique spares the dendritics, which are usually trimmed or useless. The fixation time is equivalent to surgical stapler fixation and the removal of sutures is

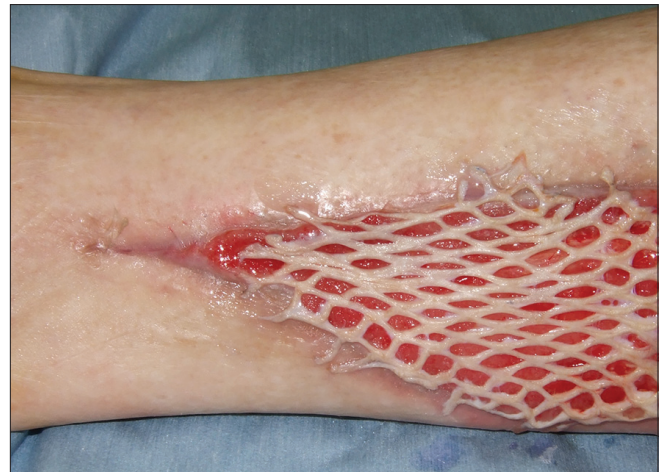

Figure 2: The dendritics of the mesh skin graft were affixed using Dermabond

not required because the graft is affixed with absorbable sutures. Local anesthesia may be necessary for pain relief during surgical stapling and sewing, but it is not necessary for the Dermabond technique.

Dermabond costs approximately \$18 per tube, whereas skin staples are \$16 and absorbable sutures are \$6 per suture. Several sutures are generally required for fixation. Therefore, the cost performance of these techniques is similar. The dendritic bonding technique is a quick and easy method for the fixation of mesh skin grafts in any patient.

REFERENCES

1. Gosain AK, Lyon VB. Plastic surgery educational foundation DATA committee. The current status of tissue glues: Part II. For adhesion of soft tissues. *Plast Reconstr Surg* 2002;110:1581-4.
2. Bain MA, Peterson EA, Murphy RX Jr. Dermabond bolster-assisted primary closure of atrophic skin. *Plast Reconstr Surg* 2009;123:e147-8.

How to cite this article: Sakamoto Y, Kishi K. "The Dendritic Bonding Technique": A Newly-devised Technique for the Fixation of Mesh Skin Graft. *J Surg Tech Case Report* 2012;4:92-3.

Source of Support: Nil, **Conflict of Interest:** None declared.