Case Report

# Intraoperative neurophysiological monitoring during separation of conjoined caudal spinal cords in pygopagus twins

**Ashima Malhotra, Vikas Gupta[1], Umesh Kumar Valecha[2], Meenu Batra[2]**

*Departments of Neuroanaesthesia, [1]Neurosurgery, and [2]Anaesthesia, BLKSSH, New Delhi, India*

## Abstract

We describe the intraoperative neurophysiological monitoring that was performed in the separation of 11-month-old pygopagus conjoined twins with fused spinal cords. The spines of the patients were fused below S2 level and they shared their thecal sac and spinal cord below that level. They also shared a common anal opening and closely placed urethral and vaginal opening. Transcranial motor evoked potentials (MEPs), electromyography (EMG), and triggered EMG (T-EMG) were recorded throughout the neuroseperation. Baseline MEP in one of the twins was suboptimal and continued to be suboptimal throughout the procedure. The other twin continued to show good MEP responses. T-EMG and EMG are guided during the successful separation and detethering of the cord. There was no fresh sensory or motor neurological deficit postoperatively. Both the patients recovered from their preoperative status as evaluated 4 months after the surgery. Monitoring two spinal cords at the same time is a challenging job. However, good monitoring systems, communication with the operating team and choice of monitoring, and utmost vigilance at crucial times helps getting the fruitful results.

**Key words:** Conjoined, electromyography, motor evoked potential, pyopagus

## INTRODUCTION

Neurophysiological intraoperative monitoring is undertaken as an effort to reduce iatrogenic neurological deficits during surgeries on the critical neural tissue. The last decade has shown remarkable progress in this field with advanced instrumentation and easy availability of complex modalities like motor evoked potentials (MEPs).[1]

Conjoined twins are monozygotic, mono-amniotic, and mono-chorionic and are always of the same sex. The most popular theory regarding their embryological origin being that they result from the secondary fusion of two originally separate monovular embryonic discs.[2] It is a rare phenomenon, estimated to range from 1 in 50,000 births to 1 in 200,000 births[3] when they are joined at the sacral region, it is called pygopagus. It is one of the rare types of conjoined twins with an overall incidence of 19% of all conjoined twins.[3]

In this case report, we describe the intraoperative neurophysiological monitoring (IONM) protocol followed and its results during the successful separation of pygopagus twins having conjoined caudal spinal cords.

**Address for correspondence:**
Dr. Ashima Malhotra, BE-161, Janakpuri, New Delhi - 110 058, India.
E-mail: ashdrmalhotra@yahoo.co.in

| Access this article online | |
|---|---|
| Quick Response Code: | Website: www.sudanmedicalmonitor.org |
| | DOI: 10.4103/1858-5000.167875 |



**How to cite this article:** Malhotra A, Gupta V, Valecha UK, Batra M. Intraoperative neurophysiological monitoring during separation of conjoined caudal spinal cords in pygopagus twins. Sudan Med Monit 2015;10:101-4.

## CASE REPORT

Healthy 11-month-old female pygopagus twins (Twin I and Twin II) were referred to the B L Kapur Super Speciality Hospital New Delhi, India for separation and reconstructive surgery. A multispecialty examination revealed that they had typical pygopagus perinea fusion but no other major abnormalities or dysmorphic features. Their combined weight was 13.8 kg. Twin I had mild calf wasting with plantar flexion weakness and Twin II had the same signs on the right. Both had mild positional scoliosis. Magnetic resonance imaging (MRI) further revealed fused anterior mons pubis with duplicated labia minora, clitoris, uretheral orifices, and vaginal introit but a single anal sphincter and a fused anal canal entering a separate rectum in each twin.

Contrast MRI of the lumbosacral spine showed low lying spinal cord with presence of spina bifida at L5–S1 level of Twin II and S2 level of Twin I. The conus medullaris was fused below S2 level with large fluid intensity which was likely to be syrinx. There was a single dysplastic sacrum [Figure 1].

### Anesthesia protocol

Since the surgery was a prolonged one involving multiple stages, anesthesia was modified as per the requirement of the surgery. Anesthesia was induced with propofol and fentanyl, muscle relaxation was achieved with atracurium and oxygen 50%, nitrous oxide 50%, and sevoflurane at a minimum alveolar concentration (MAC) of 1.0–1.5 for maintenance. Half an hour before starting the neural separation nitrous oxide was switched off, sevoflurane was reduced to MAC levels of 0.4 and intravenous anesthesia with fentanyl 3 μg/kg/h and propofol infusion 200 μg/kg/min was initiated. No neuromuscular agent was used during this period. Normothermia and stable arterial blood pressure were maintained.

### Neurophysiological monitoring protocol

All recordings were made from bipolar needle electrodes inserted 1 cm apart in the muscles depicted in Table 1 and having <5kΩ impedance. The electrodes were placed after the first stage of surgery and after placing the patients in the prone position.

The corkscrew transcranial stimulator electrodes were placed over motor cortex regions at C3 and C4 (international 10–20 electroencephalogram system). In order to avoid bite injury, a bite block was used.

The recordings were obtained on the multichannel recording system. The screen was divided into four parts which showed continuous free run and triggered electromyography (T-EMG) for both the sides of both the patients. The stack recordings for the MEP were simultaneously available continuously. However, the EMG had to be interrupted for the short duration during which the MEP stimulus was delivered.

**Table 1: Neurophysiological monitoring parameters**

| |
|---|
| Free running EMG monitoring |
| Muscle groups for recording |
| Vastus lateralis |
| Tibialis anterior |
| Abductor hallucis |
| Anal sphincter |
| Band pass filter parameters: LPF=30 Hz, HPF=1000 Hz |
| Sensitivity (amplitude level)=50 μV/div |
| Time base/speed=500 ms/div |
| Triggered EMG (direct nerve stimulation) |
| Muscle groups for recording |
| Vastus lateralis |
| Tibialis anterior |
| Abductor hallucis |
| Anal sphincter |
| Probe used for nerve stimulation: Concentric probe (bipolar in nature) |
| Parameters used for stimulation |
| Level/amplitude/intensity: 3-7 μA (varied to confirm the presence/absence of any neural tissue) |
| Bandwidth frequency=30-1000 Hz |
| Pulse duration: 200 us |
| Pulse type: Single (nontrain) |
| Time base/speed=5 ms/div |
| Stimulation frequency=4.63 Hz |
| Amplitude/sensitivity=20 μA/div |
| MEPs |
| Muscle groups for recording |
| Abductor pollicis brevis (for reference) |
| Vastus lateralis |
| Tibialis anterior |
| Abductor hallucis |
| Electrodes used for stimulation: Single corkscrew electrodes placed at C3-C4 (according to EEG 10-20 montage, to excite the primary motor cortex) |
| Stimulation parameters |
| Constant voltage type |
| Amplitude/intensity: 300V |
| Pulse type: Train |
| Rate: 333 pulses/s |
| Pulse count: 8 |
| Stimulation type: Biphasic |
| Pulse duration: 75 us |
| Time base period=10 ms/div (100 ms sweep) |
| Sensitivity/amplitude display=50 uV |
| Bandwidth frequency=30-3000 Hz |

EMG: Electromyography, LPF: Low pass filter, HPF: High pass filter, μV/div: Microvolt per division, ms/div: Millisecond per division, μA/div: Microampere per division, MEPs: Motor evoked potentials, EEG: Electroencephalogram

## RESULTS

### Motor evoked potential

The transcranial stimulation was performed after each important nerve root separation. The baseline amplitude in the left leg of Twin I was depressed and continued to be the same throughout the procedure. No fresh changes in the amplitude were noted during the surgery.

### Electromyography

Very few neurotonic discharges in single muscle groups were noticed, and the same was immediately communicated to the surgeon as they may provide the surgeon with immediate information of impending impairment. Some spontaneous EMG activities not related to intervention such as fibrillations, sharp waves, fasciculations, and repetitive discharges were noticed but not communicated to the surgeon to avoid an unwanted interruption in surgery.

### Triggered electromyography

During the sharp dissection each tissue was stimulated before severing it. During the separation of filum terminale, the plane of dissection and separation was totally based on T-EMG responses. Therefore, the T-EMG guided the surgeon during complex micro neurosurgical separation of the shared neural tissue and the identification of respective nerve roots of two twins [Figure 1].

## DISCUSSION

It was a special IONM case because of the need to monitor two nervous systems simultaneously and discretely while surgically separating their abnormal conjunction at the conus medullaris. Careful electrode management, color coding, and communication avoided confusion. The electrodes were placed after the first stage of surgery was over. All the electrodes were color coded for both the twins. The screen of the monitor was also coded as blue and pink to avoid any confusion [Figure 2]. Furthermore, the surgery required a change in position 3 times, therefore requiring utmost care for the electrodes. Although communicating any change to the surgeon we had to be very careful as to which twin we are referring to.

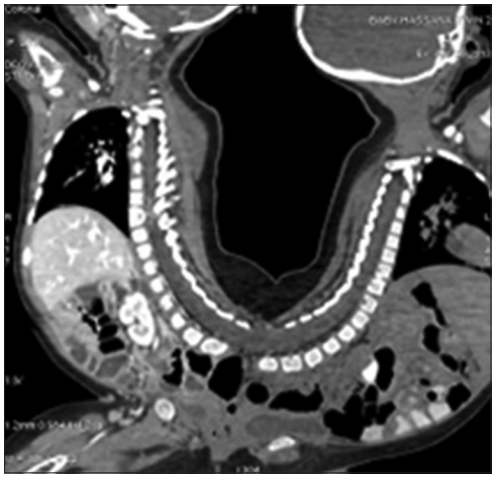

**Figure 1:** Preoperative magnetic resonance imaging

In view of the high sensitivity of the evoked potentials and myographic recordings for hypnotic agents and neuromuscular blocking agents, the anesthesia protocol is of utmost importance for neurophysiological interpretation.[4] The other challenge we encountered was that the twins shared the circulation, and, therefore, the medicines administered to one twin were affecting the other twin also. Maintaining the steady state of anesthesia for monitoring was a major challenge for us. We also discussed the essential modality for monitoring. The surface area for placement of electrodes was limited and the number of active channels on the monitoring system was also to be considered before deciding the modality.

In addition, to motor and sensory innervation to the lower extremities, the cauda equine nerve roots also contain fibers supplying anal sphincter, urethral sphincter, and urinary catheter. The innervation of anal and external urethral sphincter is under voluntary control from S2, S3, and S4 spinal segments. This set of twins shared common neural tissue below S2 and a fused sacrum.

The etiology of neurological worsening during such complex micro neurosurgeries include direct or indirect trauma to the viable neural tissue. In this particular case, the situation was even more complicated as the spinal cords of both the patients were fused. The chances of postoperative neural deficits in one or both the twins were very high as it was difficult to differentiate between the nerve roots of the two twins. The use of IONM allows identification of damage at a controllable and reversible stage allowing correction to the cause thus avoiding permanent deficits.[1] There are multiple modalities available for IONM; however, we chose EMG, T-EMG, and transcranial MEPs (TcMEP) as our technique.

MEP monitors the motor system from cortex to the neuromuscular junction. It allows individual limb assessment and since it has larger amplitude it does not require averaging as contrasting somatosensory evoked potentials (SEPs).[5] Furthermore, SEPs are unreliable for root monitoring, contain no motor information and are difficult to record quickly in young children.[6,7] Therefore, we preferred using a continuous monitoring of EMG and TcMEP over intermittent SEP, TcMEP, and EMG technique.

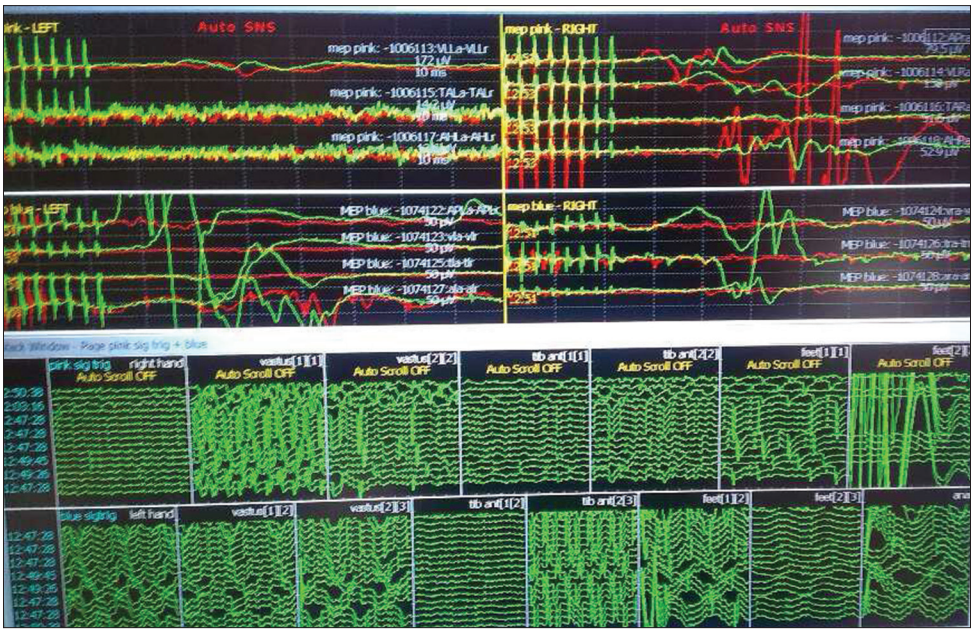


**Figure 2:** Screenshot of the intraoperative multimodal neurophysiological monitoring

The real-time updating was easily carried out at different stages of neural tissue dissection. At some points the stimulus intensity was increased to maintain stable responses but correlated well with bolus doses in anesthetic agents administered.

Since only a few neurotonic discharges were observed in the free-run EMG we believe that it probably did not impact the surgery very much. Notwithstanding, the absence of neural discharges indicated no fresh neurological damage in the monitored muscle groups. T-EMG is considered the most important modality in tethered cord separation surgery. The same was true in this particular case also, especially when the filum terminale had to be severed. Damaging the neural tissue adherent to the filum terminale would have resulted in life long anal sphincter incompetence. T-EMG served as the sole guide to avoid the viable neural tissue from being injured.

Two types of EMG monitoring can be done: Spontaneous and triggered. Monitoring of EMG activity is performed throughout the procedure. Irritation of the nerve in the surgical field produces (compound muscle action potential) in the muscles innervated by that nerve. T-EMG is used when structures within the surgical field need to be stimulated to determine if it contains any viable neural tissue. The bipolar stimulating electrodes as used in our case are preferred as they deliver more focal current as contrasts the monopolar.

In patients with such complex neural tissue multimodality IONM helps in establishing safe dissection planes at minimal risk of permanent neurological damage.[5] In the presence of densely adherent neural tissue, the T-EMG can help the surgeon to avoid the iatrogenic injuries especially in the region of conus medullaris. The MEP is considered the best modality for the assessment of the anterior column of the spinal cord.[1] Therefore, combining these two modalities compliment the sensitivity and specificity of neurophysiologic intraoperative monitoring in terms of intraoperative guidance and long-term prognostication of the neurological outcome.

### Financial support and sponsorship

Nil.

### Conflicts of interest

There are no conflicts of interest.

## REFERENCES

1. Hussain AM. A Practical Approach to Neurophysiologic Intraoperative Monitoring. New York: Demos; 2008.
2. Spencer R. Theoretical and analytical embryology of conjoined twins: Part I: Embryogenesis. Clin Anat 2000;13:36-53.
3. Hansen J. Incidence of conjoined twins. Lancet 1975;306:1257.
4. Krassioukov AV, Sarjeant R, Arkia H, Fehlings MG. Multimodality intraoperative monitoring during complex lumbosacral procedures: Indications, techniques, and long-term follow-up review of 61 consecutive cases. J Neurosurg Spine 2004;1:243-53.
5. Paradiso G, Lee GY, Sarjeant R, Fehlings MG. Multi-modality neurophysiological monitoring during surgery for adult tethered cord syndrome. J Clin Neurosci 2005;12:934-6.
6. Macdonald DB, Stigsby B, Al Homoud I, Abalkhail T, Mokeem A. Utility of motor evoked potentials for intraoperative nerve root monitoring. J Clin Neurophysiol 2012;29:118-25.
7. MacDonald DB, Al-Zayed Z, Stigsby B, Al-Homoud I. Median somatosensory evoked potential intraoperative monitoring: Recommendations based on signal-to-noise ratio analysis. Clin Neurophysiol 2009;120:315-28.