

Viper bite on the neck following a fight

**Godpower Chinedu Michael,
Ibrahim Aliyu¹,
Bukar Alhaji Grema**

Departments of Family Medicine and
¹Paediatrics, Aminu Kano Teaching
Hospital, Kano, Nigeria

Abstract

Snakebite remains a public health problem in rural communities of tropical Africa and Asia. Globally, rare snakebite presentations are increasingly been reported presumably from the intensity of efforts by researchers in this domain to showcase this recently classified neglected tropical disease. Most venomous snakebite morbidity and mortality in Nigeria are caused by *Echis ocellatus* (carpet viper) and occur in the lower and upper limbs. Limb affectation has been associated with human activity at the time of bite. Our index patient is a child engaged in pastoral activity with a rare posterior neck viper bite following a fight in a rural Nigerian community. Challenges of diagnosis, availability of affordable and appropriate anti-snake venom, inadequate education of those engaged in high risk occupations, and the dearth of specific effective first aid for neck bites were encountered.

Key words: Envenomation, neck, rural health, snake bite, viper

INTRODUCTION

Snakebite is an environmental, domestic, occupational health hazard and a neglected tropical disease that has impoverished many individuals and communities where snakebite is common.^[1] In the Nigerian savanna, *Echis ocellatus* (carpet viper) causes most snakebite morbidity and mortality though less frequently bites by *Naja nigricolis* (spitting cobra) and *Bitis arietans* (puff adder) are reported.^[2] The lower limb is the most common reported site for snakebite occurrence when snakes are trod upon during planting and harvesting activities, walking on bush paths without protective boots or herding.^[3,4] However, upper limb bites have been reported while farming, poking hands into holes during hunting, among snake charmers, from incarcerated snakes in zoos, when collecting firewood without properly screening for snakes, and others while sleeping.^[3-6] Rarely, bites on the thigh,

genital, and gluteal regions have been reported among individuals who defecate in the bush and open places in military training camps.^[7-9] Bites on the face while sleeping and chemical injuries to the eyes have also been reported when venom-spitting *Naja nigricolis* strikes.^[10,11] However, viper bites on the neck have been rarely reported.^[12] Bites on the neck are associated with first aid challenges and risk of early systemic envenoming being closer to the heart and contain the great vessels when compared to limb bites. Therefore, a case of a 10-year-old Fulani boy with viper bite on the neck during a fight is reported.

CASE REPORT

A 10-year-old male Fulani herder was brought by relatives to the emergency room of comprehensive health center in Zamko, North-central Nigeria, with painful swelling of the neck, face, scalp, and upper chest regions. He was apparently well until 4 h prior to presentation when he had a dispute with his friend that degenerated into a fight in the bush. He fell on the ground in the process and noticed a

Address for correspondence:

Dr. Godpower Chinedu Michael, Department of Family Medicine,
Aminu Kano Teaching Hospital, P.M.B. 3452, Kano, Nigeria.
E-mail: drgcmichael@gmail.com

Access this article online

Quick Response Code:



Website:

www.sudanmedicalmonitor.org

DOI:

10.4103/1858-5000.171865

This is an open access article distributed under the terms of the Creative Commons Attribution-NonCommercial-ShareAlike 3.0 License, which allows others to remix, tweak, and build upon the work non-commercially, as long as the author is credited and the new creations are licensed under the identical terms.

For reprints contact: reprints@medknow.com

How to cite this article: Michael GC, Aliyu I, Grema BA. Viper bite on the neck following a fight. Sudan Med Monit 2015;10:133-6.

strike on his neck. The snake was sighted and described as carpet viper, but could not be killed. Some local medicines were applied at the bite site and also ingested and was subsequently transported to the health center. He had an episode of vomiting of recently ingested food and medicines soon after. There was bleeding from the mouth, but had no epistaxis, hematuria, or hematochezia. There was no headache, fever, seizures, and loss of consciousness. There was also no dyspnea, drooping eyelids, dysphagia, or muscle weakness. The past medical history was not remarkable.

Physical examination revealed an agitated boy, in painful distress and had severe facial swelling. He was mildly pale, not jaundiced, with a temperature of 37.3°C. He was not dehydrated, not in respiratory distress, and had no peripheral lymphadenopathy. His pulse rate was 102 beats per minute, full volume, and regular rhythm. His systolic and diastolic blood pressures were 100 mmHg and 64 mmHg, respectively. His apex beat was at the fifth left intercostal space at the mid-clavicular line, and first and second heart sounds were heard. His weight was 22 kg. He was conscious, Glasgow Coma Scale of 15 (E4V5M6). Pupillary and ptosis assessments were precluded by severe facial swelling. There was marked swelling of the neck with leading edges toward the chest and scalp [Figure 1]. There were two bleeding fang puncture wounds at the posterior aspect of neck at the level of the hair line on the midline painted with local concoctions. Findings in the respiratory, gastrointestinal, and genitourinary systems were not remarkable.

The leading edges of the swelling were marked with pen for monitoring progression while vital signs and signs of neurotoxicity (dysphagia, dyspnea, and muscle weakness) were monitored. The 20 min whole blood

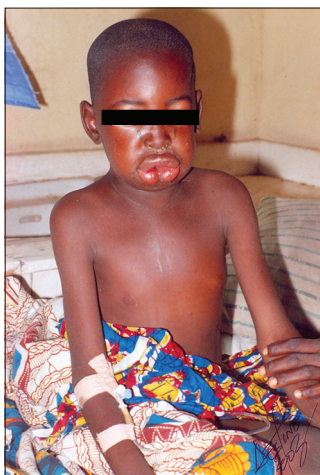

Figure 1: 10-year-old Fulani herds' boy with posterior neck viper bite and coagulopathy, severe edema of the scalp, face, and chest

clotting time (20MWBCT) was un-clotted and the packed cell volume (PCV) was 28%. Ten milliliters of *Echis* monospecific antivenom, South African Institute for Medical Research (SAIMR) was given over 10 min. Vital signs were monitored for immediate allergic reactions. The 20MWBCT was repeated 6 hourly and un-clotted results were followed with repeat antivenom. He had received 20 ml of antivenom when 20MWBCT became clotted. He also received 25 mg of intravenous hydrocortisone and 500 mg of ampicillin/cloxacillin 6 hourly for the first 24 h to reduce tissue inflammation and prophylaxis for the high-risk wound. He had wound cleaning with antiseptic solution and intramuscular tetanus toxoid when 20MWBCT had clotted. The swelling progression gum bleeding subsided. His repeat PCV was 27% on the 5th day and by the 6th day of admission he was discharged from hospital with hematinics. On the follow-up visit a week later, there was no recurrence of symptoms, swellings have completely resolved, PCV was 31%, wound had completely healed, and counseling for secondary prevention of bite was given.

DISCUSSION

Most snake bites in sub-Saharan Africa occur in rural communities among young men engaged in agrarian or pastoral activities.^[2] Of interest in this report is the victim's immediate activity at the time of bite and the part of the body involved. He was involved in a dispute with his colleague which degenerated into a fight. Falling on the ground in that process resulted in a posterior neck bite. Combat activities have been hardly associated with snakebite except in those reported among American soldiers in the field and in Indian military training camp.^[7,8] This suggests that snakebite can be associated with virtually any human activity in areas with high snakebite prevalence. Parents who engage children in high risk activities such as herding must emphasize strict vigilance at all times. In addition, children should be accompanied by adults. Child labor is not easily recognized in most traditional Nigerian societies as children are assigned activities that ordinarily should be for adults. It is probable that many under-aged children die from unreported snakebites while herding or engaged in agrarian activities. Furthermore, posterior neck bites have been rarely reported when compared with other parts of body and often associated with fatality,^[12] though facial bites have been reported during sleep.^[10] Bite site location is largely related to the human activity and the offending snake location at the time of bite. *Echis ocellatus* dwells in rocky habitations and naturally crawls on the ground.^[13] Most human-snake encounters occur while the snake is on the ground; hence most bites are on the lower limbs.

The use of traditional medications (topical and oral) is common in the region despite reports of their ineffectiveness and potential for complicating bite wounds.^[14] The index case applied local medicines to bite site and ingested same. This was a justification for antibiotics use in his management.

Nonidentification of the offending snake in hospital had been reported by Michael *et al.*, where as much as 25% of patients in a study at the center were unidentified.^[14] However, most communities where snakebite is prevalent the common snake species are known to and identifiable by members. The diagnostic challenge of snake nonidentification in hospital in this case was overcome by utilizing careful history from witnesses who sighted the snake. The *Echis ocellatus* was familiar to index patient's community and his father had a viper bite 3 years earlier. The presence of features of coagulopathy was also used in the approach to management of the index case, similar to that reported by Blaylock.^[15]

Factors that have been associated with severe venomous snake bite include young age because larger envenomation relative to body size, ill health, bites on the trunk, neck, face or vessels, bites by large snakes, presence of bacteria in venom or mouth of snake, and mobilization and exertion immediately following a bite.^[16,17] The index case was of young age, not malnourished, had a bite on the neck with no restriction of neck movement, and evidence of coagulopathy. This case was managed as severe envenomation. The main stay of management of severe envenomation is the use of anti-snake venom which averts death in over 80% of carpet viper bites.^[18] The choice of anti-snake venom is determined by offending snake species. In the absence of physical identification of the snake and nonavailability of venom detection kits, polyspecific are preferred over monospecific antivenom because other snake species common in the area have also been associated with swelling and coagulopathy.^[15] The polyspecific antivenom in Nigeria commonly contains sera for *Naja nigricolis*, *Bitis arietans*, and *Echis carinatus* venoms. *Echis ocellatus* is one of the eight subtypes of *Echis carinatus*.^[13] For the index case, there was no free polyspecific antivenom supply at the time and the father had insufficient funds to afford out-of-pocket purchase. The available SAIMR monospecific antivenom was used in its place with favorable outcome as seen in Figure 2. This underscores the need for simplified and flexible treatment protocols in low-resource setting and referral for deserving patients to specialized centers.

Snakebite first aid include reassuring the victim and ensuring that the victim's affected limb is immobilized with splint or sling to reduce toxin dissemination.^[2] To

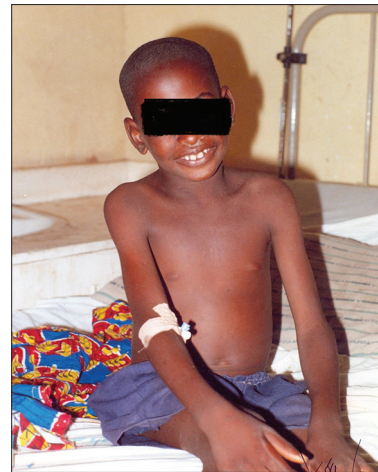

Figure 2: Six days after commencement of treatment

our knowledge, there is no documented specific first aid for neck bites apart from reassurance. This is probably because the neck is close to the heart, making any splinting ineffective. In addition, there is a danger for “tourniquet effect” with pressure immobilization, especially when applied by the untrained. Thus, counseling of neck bite victims should include reassurance of victim and expediting movement to hospital.

CONCLUSION

While neck bites attract similar management challenges as limb bites, preventive measures should include education of parents and caregivers to children on the need to guide their children properly, especially the need to observe absolute vigilance when performing such high risk activities such as herding. Cost and availability of effective anti-snake venom remain a recurring problem in most reports in Nigeria. The federal government must intensify efforts toward universal health coverage of the national health insurance scheme that would guarantee access to quality health care for snakebite patients in Nigeria.

Declaration of patient consent

The authors certify that they have obtained all appropriate patient consent forms. In the form the patient(s) has/have given his/her/their consent for his/her/their images and other clinical information to be reported in the journal. The patients understand that their names and initials will not be published and due efforts will be made to conceal their identity, but anonymity cannot be guaranteed.

Financial support and sponsorship


Nil.

Conflicts of interest

There are no conflicts of interest.

REFERENCES

- Harrison RA, Hargreaves A, Wagstaff SC, Faragher B, Laloo DG. Snake envenoming: A disease of poverty. *PLoS Negl Trop Dis* 2009;3:e569.
- Warrell DA, Arnett C. The importance of bites by the saw-scaled or carpet viper (*Echis carinatus*): Epidemiological studies in Nigeria and a review of the world literature. *Acta Trop* 1976;33:307-41.
- Fadare JO, Afolabi OA. Management of snake bite in resource-challenged setting: A review of 18 months experience in a Nigerian hospital. *J Clin Med Res* 2012;4:39-43. Available from: <http://www.academicjournals.org/JCMR>. [Last accessed on 2015 Jul 26].
- Iliyasu G, Halliru ST, Habib ZG, Tiamiyu AB, Dayyab FM, Abubakar SB, *et al.* Blister and bulla following snake bite in Nigeria: A prospective cohort study. *Int J Trop Dis Health* 2014;4:1069-77.
- Madaki JK, Obilom R, Mandong BM. Clinical presentation and outcome of snake bite patients at Zamko comprehensive health centre, Langtang, Plateau state. *Highland Med Res J* 2004;2:61-8.
- Singh UK, Layland CF, Suman S, Prasad R. Snake bite. In: *Poisoning in Children*. 2nd ed. New Delhi: Jaypee Medical Publications; 2001. p. 74-86.
- Shiau DT, Sanders JW, Putnam SD, Buff A, Beasley W, Tribble DR, *et al.* Self-reported incidence of snake, spider, and scorpion encounters among deployed U.S. military in Iraq and Afghanistan. *Mil Med* 2007;172:1099-102.
- Singh J, Bhoi S, Gupta V, Goel A. Clinical profile of venomous snake bites in North Indian Military Hospital. *J Emerg Trauma Shock* 2008;1:78-80.
- Arshad A, Azfar M, Munawwar H, Jawed UA. Snake bite on scrotum – A case report. *Pan Afr Med J* 2011;10:25.
- Belonwu RO, Gwarzo GD. Envenomation secondary to facial snake bite: Report of a rare occurrence. *Niger J Paediatr* 2015;42:162-4.
- Warrell DA, Ormerod LD. Snake venom ophthalmia and blindness caused by the spitting cobra (*Naja nigricollis*) in Nigeria. *Am J Trop Med Hyg* 1976;25:525-9.
- Lukšić B, Culic V, Stricevic L, Brizic I, Poljak NK, Tadic Z. Infant death after nose-horned viper (*Vipera ammodytes ammodytes*) bite in Croatia: A case report. *Toxicon* 2010;56:1506-9.
- Freyvogel TA. Poisonous and venomous animals in East Africa. *Acta Trop* 1972;29:401-51.
- Michael GC, Thacher TD, Shehu MI. The effect of pre-hospital care for venomous snake bite on outcome in Nigeria. *Trans R Soc Trop Med Hyg* 2011;105:95-101.
- Blaylock RS. The identification and syndromic management of snake bite in South Africa. *SA Fam Pract* 2005;47:48-53.
- Paul VK. Animal and insect bites. In: Singh M, editor. *Medical Emergencies in Children*. 2nd ed. New Delhi: Sagar Publications; 1993.
- Chang KP, Lai CS, Lin SD. Management of poisonous snake bites in Southern Taiwan. *Kaohsiung J Med Sci* 2007;23:511-8.
- Habib AG. Antivenom Therapy Following Snakebite: Effectiveness and Strategies for Delivery in West Africa. Honolulu, Hawaii, USA: 17th World Congress of International Society of Toxinology Animal and 4th Venom Week (USA); 2012.



Author Help: Reference checking facility

The manuscript system (www.journalonweb.com) allows the authors to check and verify the accuracy and style of references. The tool checks the references with PubMed as per a predefined style. Authors are encouraged to use this facility, before submitting articles to the journal.

- The style as well as bibliographic elements should be 100% accurate, to help get the references verified from the system. Even a single spelling error or addition of issue number/month of publication will lead to an error when verifying the reference.
- Example of a correct style
Sheahan P, O'leary G, Lee G, Fitzgibbon J. Cystic cervical metastases: Incidence and diagnosis using fine needle aspiration biopsy. *Otolaryngol Head Neck Surg* 2002;127:294-8.
- Only the references from journals indexed in PubMed will be checked.
- Enter each reference in new line, without a serial number.
- Add up to a maximum of 15 references at a time.
- If the reference is correct for its bibliographic elements and punctuations, it will be shown as CORRECT and a link to the correct article in PubMed will be given.
- If any of the bibliographic elements are missing, incorrect or extra (such as issue number), it will be shown as INCORRECT and link to possible articles in PubMed will be given.