

**OPEN ACCESS**

Full open access to this and thousands of other papers at <http://www.la-press.com>.

## Unusual Presentation of Multiple Nerve Palsies with Granulomatous Encephalitis Due to *Acanthamoeba* Species

Vinay Khanna<sup>1</sup>, Aparna Pai<sup>2</sup>, Anirudda Deshpande<sup>2</sup>, K.V. Chakradhar<sup>1</sup> and Chiranjay Mukhopadhyay<sup>1</sup>

<sup>1</sup>Department of Microbiology, Kasturba Medical College, Manipal University, Karnataka, India. <sup>2</sup>Department of Neurology, Kasturba Medical College, Manipal University, Karnataka, India. Corresponding author email: [drvinay2004@yahoo.com](mailto:drvinay2004@yahoo.com)

---

**Abstract:** *Acanthamoeba spp* is one of the common protozoa in soil, usually found in fresh water and other habitats. We are presenting a case of Granulomatous amoebic encephalitis presented with unusual symptoms of third, fourth, sixth, and seventh nerve palsy with diplopia, ptosis, and migraine. Differential diagnosis of tuberculous (TB) meningitis was initially considered but was ruled out by CSF TB PCR. There was no history of exposure to sources such as fresh water ponds and contaminated swimming pools. CSF wet mount and culture confirmed the diagnosis of *Acanthamoeba spp*. Specific antiparasitic therapy was started and patient improved with successful resolution of symptoms.

**Keywords:** *Acanthamoeba spp*, Granulomatous amoebic encephalitis, Nerve palsies

---

*Human Parasitic Diseases* 2013;5 1–5

doi: [10.4137/HPD.S12187](https://doi.org/10.4137/HPD.S12187)

This article is available from <http://www.la-press.com>.

© the author(s), publisher and licensee Libertas Academica Ltd.

This is an open access article published under the Creative Commons CC-BY-NC 3.0 license.

## Introduction

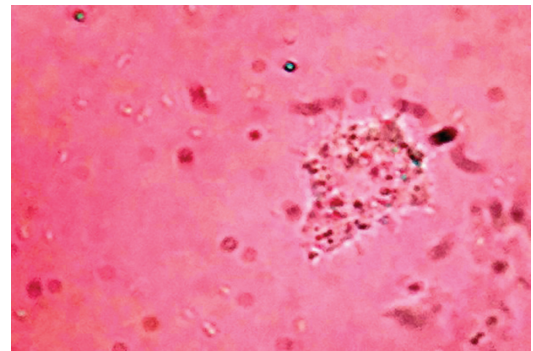
Free-living amoebae that cause infections of the central nervous system (CNS) in humans include *Naegleria fowleri*, *Acanthamoeba* species, and *Balamuthia mandrillaris*.<sup>1</sup> *N. fowleri* usually cause acute fulminant meningoencephalitis in young immunocompetent individuals, whereas *Acanthamoeba spp* usually cause chronic, but fatal, encephalitis in immunocompromised hosts. This often referred to as granulomatous amoebic encephalitis (GAE). This infection occurs commonly in patients with diabetes, malignancies, malnutrition, systemic lupus erythematosus, and AIDS but cases have been reported in immunocompetents as well.<sup>3</sup> The organisms gain access through the skin or upper respiratory tract and reaches the CNS through haematogenous routes, where it causes severe oedema and hemorrhagic necrosis.<sup>4</sup>

## Case Report

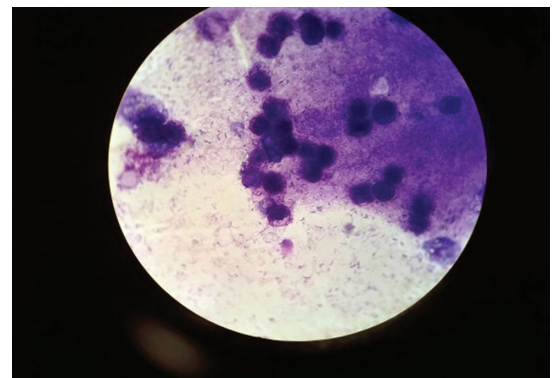
A woman in her mid-20s with past history of migraine without aura for 6 to 7 years presented with change in character of headache. It was associated with double vision for 3 months and ptosis in the left eye for the last 10–12 days. It was insidious in onset. There was no history of fever, conjunctival suffusion, seizures, or altered sensorium. On admission, general examination revealed patient was conscious and vital signs were stable. On neurological examination, she was found to have right 7th nerve lower motor neuron (LMN) palsy, complete left 3rd nerve with pupillary involvement, as well as palsy on the left 4th and left 6th nerves.

Her laboratory parameters were all within normal limits except mildly elevated white blood cell count, which was 13,600/mm<sup>3</sup> with neutrophilic predominance (70%). Lumbar puncture yielded a turbid cerebrospinal fluid (CSF) which, on microscopic examination, revealed occasional lymphocytes in the background of degenerating cells. The analysis of CSF showed predominantly lymphocytes, low proteins, and high glucose levels. CSF wet mount showed amoebic trophozoites with acanthopodia (Fig. 1). The CSF was sent for bacterial culture and sensitivity assessment, and tuberculosis polymerase chain reaction (TB PCR) analysis to rule out bacterial meningitis and tuberculous (TB) meningitis. It was found to be negative for both bacterial and TB meningitis. Giemsa stain (Fig. 2) of CSF culture revealed

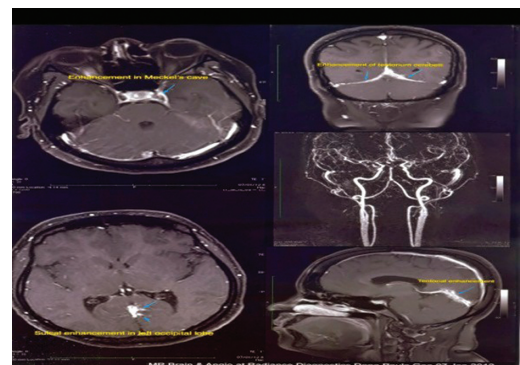
amoebic cysts, suggesting *Acanthamoeba spp*. Brain imaging showed multiple scattered hyper intensities along the Meckel's cave, Tentorium cerebelli, and a sulcal enhancement in the left occipital lobe indicating a chronic inflammatory nature of the disease and involvement of the cranial nerves (Fig. 3). Diagnosis was confirmed by isolation of acanthamoeba from non-nutrient medium after inoculation and overlay with *Escherichia coli* (Fig. 4).



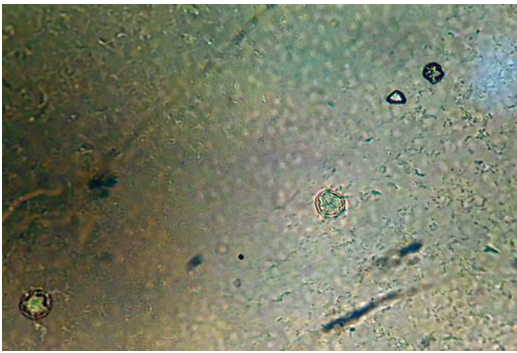
**Figure 1.** CSF wet mount showing trophozoite of *Acanthamoeba spp*.



**Figure 2.** Giemsa stain showing cysts of *Acanthamoeba spp*.



**Figure 3.** Contrast Enhanced Computed Tomography of brain showing diffuse edema.



**Figure 4.** CSF culture showing cysts of *Acanthamoeba* spp.

Specific therapy was started with rifampicin, cotrimoxazole, and fluconazole. Patient symptoms resolved and general condition improved with treatment. The prognosis and severity of the disease was explained to patient and the relatives. In view of financial constraints they were not willing to stay for further treatment. Hence patient was discharged against medical advice and asked to follow up in the outpatient clinic.

## Discussion

It was not definite how the patient contracted the infection as there was no history suggesting exposure to contaminated water including swimming in contaminated water, usage of contact lens, or skin trauma. There have been, however, several case reports suggesting occurrence of this infection through aerosolized route.<sup>4</sup> Due to absence of definite history of source exposure, possible inhalation of cysts with further spread to circulatory system cannot be ruled out in our case. Differential diagnosis of bacterial and TB meningitis was taken into consideration, but was ruled out through CSF culture and TB PCR. There are few case reports of acanthamoeba keratitis from India, however reports of GAE with multiple nerve palsies are quite rare.<sup>10</sup> Other rare manifestations of disease include mental status changes, seizures, hemiparesis, meningismus, and ataxia. Due to these varied clinical manifestations of this disease, it is a challenge to make correct diagnosis. Based on clinical suspicion, the diagnosis was confirmed by CSF wet mount and culture.<sup>5</sup> Fortunately in this case, we could both identify the pathogen in the smear as well as isolated it in culture.

*Acanthamoeba* spp mainly affects immuno compromised patients however there have been reports of

GAE in immunocompetent individuals.<sup>6,7</sup> Systemic lupus erythematosus (SLE) and diabetes mellitus were considered as risk factors for the development of this infection.<sup>10</sup> In the past decade there have been a few case reports of *Acanthamoeba* meningitis and intracranial lesions worldwide (Table 1).

In our case, no obvious immunodeficiency states were identified. The source of the infection was not clear and none of the significant risk factors for infection were found.

There is no standard drug regimen for the treatment of GAE. *In vitro* studies to determine the sensitivity pattern of antiparasitic effect against this organism have not shown any persistent amoebicidal activity. Drugs such as pentamidine, rifampicin, cotrimoxazole, and fluconazole have been used with variable success.<sup>8,9</sup> In present case, a combination of rifampicin, cotrimoxazole, and fluconazole was used. Long term therapeutic response in this case could not be assessed as the patient was discharged against medical advice, thereby chance of full recovery of our patient was guarded.

Due to high fatality rate and complications in immunocompetents, it is necessary to have a high index of suspicion to recognize it early, especially in those cases where CSF examination is negative for common organisms and where conventional therapy usually failed. GAE has a high mortality rate among immunocompromised and most of the immunocompetent patients develop some sequelae of this disease. The present case is one of the few cases in which the patient survived the infection but developed multiple cranial nerve palsies as complication.

## Conclusion

Due to delay in diagnosing the disease and lack of optimal antimicrobial therapy, most of GAE goes unnoticed. It is better to have high suspicion of acanthamoeba infection even in immunocompetent patients with signs and symptoms of chronic meningoencephalitis and focal neurological deficit. Prompt diagnosis and early treatment can save patients life and improve quality of life.

## Author Contributions

Conceived and designed the experiments: AP. Analyzed the data: AD. Wrote the first draft of the manuscript: KVC. Contributed to the writing of the

**Table 1.** List of case reports on *Acanthamoeba* infections published over the years.

Year	Author	Age/Sex	Investigation done	Treatment given	Outcome	Journal reference
1993	Sharma PP et al	12 Y/F	CSF wet mount and culture	Cotrimoxazole	Successful	<i>Indian Pediatr.</i> 1993;30:1219–22
2002	Hamide et al	45 Y/F	CSF wet mount and Giemsa preparation	Rifampicin, cotrimoxazole, fluconazole, ceftriaxone, albendazole	Successful	<i>Neurol India.</i> 2000;50:484–6
2003	Velho et al	26 Y/F	Postmortem histopathology from biopsy		Died	<i>J Neurosurg.</i> 2003;99:572–4
2006	Petry F et al	64 Y/F	CSF wet mount, Giemsa stain, culture	Fluconazole, rifampicin, metronidazole, sulfadiazine	Successful	<i>J Clin Microbiol.</i> 2006;44:1903–4
2008	Kaushal et al	63 Y/F	CSF wet mount, culture	Amphotericin B, fluconazole, rifampicin, cotrimoxazole	Died	<i>Indian J Med Microbiol.</i> 2008;26:182–4
2009	Saxena et al	15 Y/F	CSF wet mount, culture	Rifampicin, cotrimoxazole, fluconazole	Successful	<i>Indian J Pediatr.</i> 2009;76:1063–4
2009	Ranjan et al	25 Y/F	Wet mount of Intracranial cyst fluid	Rifampicin, cotrimoxazole, fuconazole	Successful	<i>Surg Neurol.</i> 2009;72,185–9
2011	Binesh et al	5 Y/F	Postmortem CSF wet mount and culture	Corticosteroid and ceftriaxone	Died	<i>BMJ Case Reports.</i> 2011
2013	Vinay et al	30 Y/F	CSF wet mount CSF Giemsa smear preparation, CSF culture	Fluconazole, rifampicin and cotrimoxazole	Successful	Current study

manuscript: VK. Agree with manuscript results and conclusions: VK. Jointly developed the structure and arguments for the paper: AD. Made critical revisions and approved final version: CM. All authors reviewed and approved of the final manuscript.

## Funding

Author(s) disclose no funding sources.

## Competing Interests

Author(s) disclose no potential conflicts of interest.

## Disclosures and Ethics

As a requirement of publication the authors have provided signed confirmation of their compliance with ethical and legal obligations including but not limited to compliance with ICMJE authorship and competing interests guidelines, that the article is neither

under consideration for publication nor published elsewhere, of their compliance with legal and ethical guidelines concerning human and animal research participants (if applicable), and that permission has been obtained for reproduction of any copyrighted material. This article was subject to blind, independent, expert peer review. The reviewers reported no competing interests.

## References

1. Ma P, Visvesvara GS, Martinez AJ, Theodore FH, Dagget PM, Sawyer TK. Naegleria and Acanthamoeba infections: review. *Rev Infect Dis.* 1990;12(3):490–513.
2. Marciano-Cabral F. *Acanthamoeba* spp. as agents of disease in humans. *Clin Microbiol Rev.* 2003;16(2):273–307.
3. Martinez AJ. Infection of the central nervous system due to Acanthamoeba. *Rev Infect Dis.* 1991;13 Suppl 5:S399–S402.
4. Martinez AJ, Visvesvara GS. Free-living, amphizoic and opportunistic amebas. *Brain Pathol.* 1997;7(1):583–598.
5. Wiley CA, Safrin RE, Davis CE. *Acanthamoeba* meningoencephalitis in a patient with AIDS. *J Infect Dis.* 1987;155(1):130–132.



6. Rodueriguez R, Mendez D, Molina O, et al. Central nervous system infection by free living amebas: report of 3 Venezuelan cases. *Rev Neurol*. 1998;26(154):1005–1008.
7. Lalitha M, Anandi V, Srivastava A, Thomas K, Cherian AM, Chandi SM. Isolation of *Acanthamoeba culbertsoni* from a patient with meningitis. *J Clin Microbiol*. 1985;21(4):666–667.
8. Slater CA, Sickel JZ, Visvesvara GS, Pabico RC, Gaspari AA. Successful treatment of disseminated acanthamoeba infection in an immunocompromised patient. *N Engl J Med*. 1994;331:85–87.
9. Cleland PG, Lawande RV, Onyemelukwe G, Whittle HC. Chronic amoebic meningoencephalitis. *Arch Neurol*. 1982;39(1):56–57.
10. Shirwadkar CG, Samant R, Sankhe M, et al. *Acanthamoeba* encephalitis in patient with systemic lupus, India. *Emerg Infect Dis*. 2006;12(6):984–986.