

# Comparison of axial and sagittal views for angulation, cuspal tip distance, and alveolus width in maxillary impacted canines using CBCT

N M Uday, Prashanth Kamath, Vinod A R Kumar<sup>1</sup>, Arun B R Kumar, Rajat Scindhia, M B Raghuraj, Joe Rozario

Department of Orthodontics and Dentofacial Orthopaedics, Dr. Syamala Reddy Dental College Hospital and Research Centre, <sup>1</sup>Consultant Oral And Maxillofacial Radiologist, ORAL-D (Digital Dental Diagnostic Centre), Bengaluru, Karnataka, India

## ABSTRACT

**Introduction:** Three-dimensional (3D) cone-beam computed imaging allows localization of impacted canines, using spatial relationships with excellent tissue contrast. The aim of this study was to compare different views to assess exact localization of impacted maxillary canine using Kodak 9000 (France). **Materials and Methods:** In this study, 24 consecutive subjects with seven bilateral (considered as two samples) and 17 unilateral impacted maxillary canines were selected and subjected to cone-beam computed tomography (CBCT); axial and sagittal views were captured to localize the exact position of the impacted canine to the occlusal plane and its relation with adjacent incisors. **Results:** Mean angulation of 37.57° and 40.27° for axial (horizontal) and sagittal (vertical) views, respectively. A correlation was found between the proximity of the impacted canine to the incisors and their resorption ( $\chi^2$ : 19.584). Cuspal tip distance was higher in sagittal view than in the axial view ( $P < 0.05$ ). **Conclusion:** Depending upon the type of impaction both sagittal and axial views showed significant variation with axial view having predominant values. Therefore, CBCT images can allow the operator to assess the direction of impacted canine, amount of surrounding alveolus bone, local anatomic considerations, resorption, and condition of adjacent teeth; thereby, improving quality of orthodontic treatment planning and as well as surgical approach.

**Key words:** Cone-beam computed tomography, impacted canines, localization, sagittal and axial views

## Introduction

The cornerstone of the dental arches 'the canines' are one among the most frequently impacted teeth after the third molars, with a prevalence ranging from approximately 1-3% due to its multifactorial etiology.<sup>[1]</sup> Maxillary canines are important esthetically and functionally, but impacted canines are more difficult and time consuming to treat. Moreover, impacted canines vary greatly in the inclination

and location and can lead to resorption of neighboring incisors, as well as cystic degeneration.<sup>[2,3]</sup> The orthodontic surgical management of impacted canines requires an accurate diagnosis and localization.<sup>[4]</sup>

Historically, several radiographic techniques have been recommended, including periapical, occlusal, panoramic, and cephalometric radiographs or a combination of this approaches.<sup>[3]</sup> When using these techniques, however, the appearance of the longitudinal axis and the relationship with the neighboring bony and dental structures are often inaccurate because these complex structures overlap in the maxillofacial region. In such cases, therefore, several authors have used computed tomography (CT)—particularly spiral CT—for localization of the impactions and for evaluation of resorption of incisors, due to the excellent tissue contrast and precise three-dimensional (3D) images afforded by this technique.<sup>[4-6]</sup>

### Access this article online

#### Quick Response Code:



**Website:**  
www.jorthodr.org

**DOI:**  
10.4103/2321-3825.125919

**Address for correspondence:** Dr. N M Uday, Department of Orthodontics and Dentofacial Orthopaedics, Dr. Syamala Reddy Dental College Hospital and Research Centre, #111/1 SGR College Main Road, Munnekolala, Marathalli (post), Bengaluru - 560 037, Karnataka, India. E-mail: udaynm@gmail.com

However, the relatively high radiation dose and high cost have restricted its use in the evaluation of tooth impaction.<sup>[1,3]</sup>

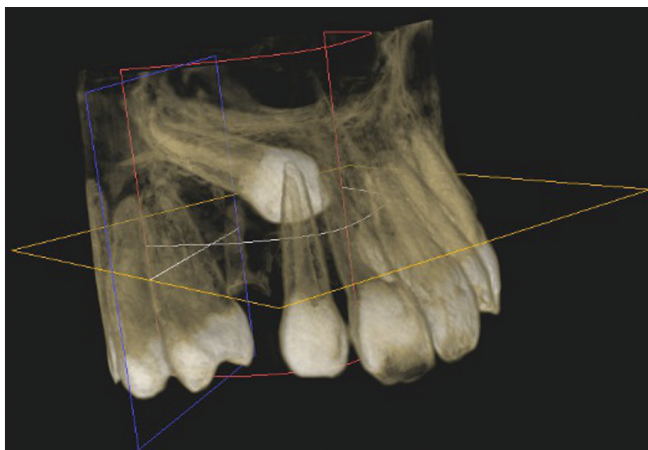
In recent years, a series of cone-beam computed tomography (CBCT), units have been developed and used for localization of tooth impaction; these machines use cone-shaped radiation to gather information in the maxillofacial region, with high spatial resolution and significantly decreased radiation doses.<sup>[7,8]</sup> Hence, precise 3D localization of impacted canines can be the central and contemporary to their clinical management.

## Materials and Methods

In the above study, sample of 24 patients presenting to the Department of Orthodontics and Dentofacial Orthopedics, Dr Syamala Reddy Dental College, with impacted or ectopically erupting maxillary canines were considered. This group of patients showed a definite indication that they would benefit from this modality of investigation. These patients were referred to Oral-D Diagnostic Center Bengaluru, Karnataka, India for localization of impacted teeth, using CBCT (Kodak 9000 France). Impacted canines were localized using the CBCT images, in coronal, axial, and sagittal views assessing their inclination/angulation, distance from occlusal plane, proximity to the adjacent teeth, and causing resorption [Figure 1].

### Objectives of this Study Were to Determine

1. Localization: In three views-axial, coronal, and sagittal
  - Angulation (inclination) of the canine to the midline.
  - Cuspal tip distance from the occlusal plane line.
2. Alveolus width was measured in axial and sagittal views.



**Figure 1:** Three-dimensional (3D) reconstructed image of maxillary impacted canine using Kodak 9000

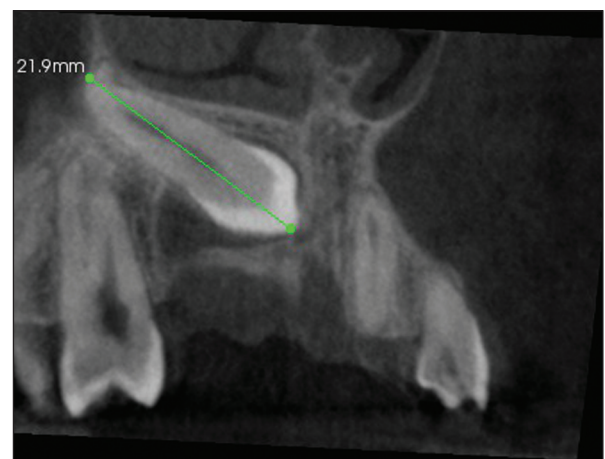3. Root resorption and proximity of the adjacent teeth was graded in one of the following four categories based on the grading system suggested by Ericson and Kurol:<sup>[3]</sup>
  - No resorption: Intact root surfaces
  - Mild resorption: Resorption midway to the pulp or more, the pulp lining being unbroken.
  - Moderate resorption: The pulp is exposed by the resorption, the involved length of the root is less than one third of the entire root.
  - Severe resorption: The pulp is exposed by the resorption, and the involved length is more than one-third.

## Method

The longitudinal axis of the impacted canine was defined with the aid of a 3D distance calibration toolbar in the Kodak 9000 software, which automatically connected a line between the cusp tip and the root apex in the sagittal view after these two points were selected by the users. On the axial plane, the distances from the cusp tip to the midline of the maxilla were measured perpendicularly, and the angle between the long axis of the canine and mid-sagittal plane was calculated [Figures 2 and 3].

To determine reliability and repeatability of this method, measurements were taken by two operators, an orthodontist and by a radiologist (time interval-1 day) on the original reoriented volumetric image, and the mean of the two readings was considered.

The position on the occlusal plane where the normally erupted canine cusp tip should be located was used as a control reference point. The occlusal plane was defined as the plane touching the incisal edge of a central maxillary incisor to the mesiobuccal cusp tips of the first maxillary molars.



**Figure 2:** A CBCT image showing line connecting the long-axis of impacted maxillary canine

## Statistical Analysis

A Student's *t*-test was carried out to compare the differences between the different variations of impaction. Decision Criterion: We compare the *P*-value with the level of significance. If  $P < 0.05$ , we reject the null hypothesis and accept the alternate hypothesis. If  $P \geq 0.05$ , we accept the null hypothesis.

## Results

### Characteristics of Patients and Variations of Impacted Canines

Among the 24 patients, eight were male and 16 cases were female. Ages ranged from 14 to 27 years, with mean age of  $17.29 \pm 3.52$  and median age of 16.5 years. Seventeen patients presented with unilateral impactions, while seven patients had bilateral impactions. Among the 17 unilateral impactions, 10 of them were on left side and six on right side.<sup>[9]</sup> One was in the midline and three cases had retained deciduous teeth [Tables 1 and 2].

### 3D Localization of Canines Determined by Angulation and Cuspal Tip Distances from the Occlusal Plane

Measurements showed that the horizontal angle of the impacted maxillary canine in the axial view varied from  $10^\circ$  to  $73^\circ$  with a mean angle of  $37.57^\circ$  and vertical angle in sagittal view varied from  $0^\circ$  to  $75^\circ$  with a mean of  $40.27^\circ$  [Table 3].

**Table 1: Gender distribution in the study sample**

Gender	<i>n</i>	%
Male	8	33
Female	16	67
Total	24	100

**Table 2: Mean age in the study sample (overall and according to gender)**

Gender	Mean	Standard deviation	SE of Mean	Median	Min	Max
Overall	17.29	3.52	0.72	16.5	13	27
Male	20.13	4.45	1.57	20.5	15	27
Female	15.88	1.82	0.46	16.0	13	20

SE: Standard error

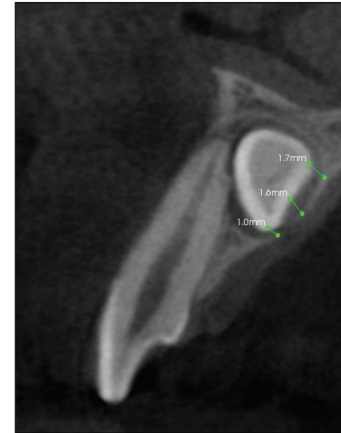
**Table 3: Comparison of angulation between axial and sagittal views**

View	Mean	Standard deviation	SE of Mean	Mean difference	<i>t</i>	<i>P</i> -value
Axial	37.57	16.15	2.95			
Sagittal	40.27	19.94	3.64	-2.700	-0.576	0.567

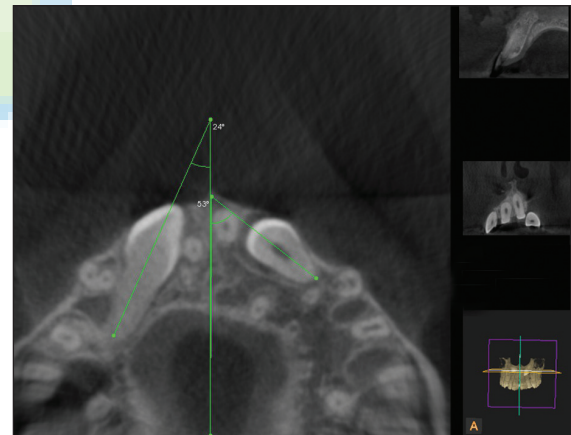
SE: Standard error. Higher mean angulation was recorded in sagittal view compared to axial view, but the difference between them was not statistically significant ( $P > 0.05$ )

Higher mean angulation was recorded in sagittal view compared to axial view, but the difference between them was not statistically significant ( $P > 0.05$ ). But different views are required for different type of impaction, since it is essential to consider the long axis of the impacted canine to orient its angulation to the mid-sagittal plane.

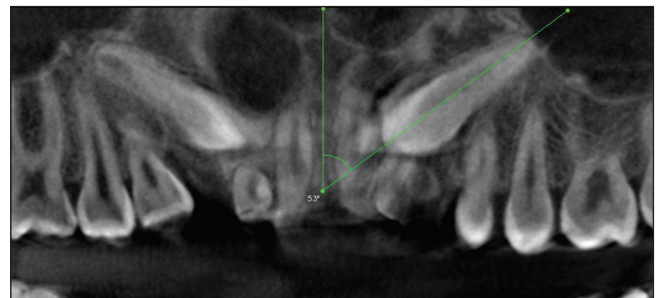
Hence, in the study axial view was considered for canines that were horizontally and for mesiopalatally impacted the angulation was better oriented in sagittal plane [Figures 4 and 5].



**Figure 3:** Sagittal image showing the width of alveolus at different sites depending upon the site of impaction



**Figure 4:** Axial view showing the angulation of bilaterally impacted canines to the midsagittal plane



**Figure 5:** Sagittal view of the same patient considered for comparison of the angulation to the midsagittal plane



Higher mean cuspal tip distance was recorded in sagittal view compared to axial view and the difference between them was found to be statistically significant ( $P < 0.05$ ).

Measurements reveal that among the seven mesiopalatally and two horizontally impacted canines showed a much relative readings to the midsagittal plane in the axial view than in the sagittal plane with a mean difference of  $5.33 \pm 0.4$  mm, signifying that in such conditions axial view gives a better position of the cuspal tip of the impacted canines for surgical approach [Figure 6 and Table 4].

### Assessment of Alveolus Width

Higher mean alveolus width was recorded in sagittal view compared to axial view and the difference between them was found to be statistically significant ( $P < 0.05$ ) [Table 5].

### Resorption and Proximity of the Adjacent Teeth

Of the 30 sample, 26 of the cases showed resorption of the adjacent incisors resulting in a resorption rate of 53%. Among the 26 cases, 18 showed resorption with contact relationship of adjacent teeth with close proximity of 0.5 mm in the axial view. While eight patients had resorption of the adjacent incisors with no contact from the impacted canines.

Higher number of samples with touch proximity had moderate resorption, whereas higher number of samples with no touch proximity had mild resorption. The association between resorption and proximity was found to be statistically significant ( $P < 0.001$ ) [Figure 7 and Table 6].

In total, the resorption were mild in 10 cases, moderate in 13, and severe in three patients; graded according

to Ericson and Kurol grading system.<sup>[5]</sup> Whereas root resorption occurred only in lateral incisors in 13 impacted canines, only on the central incisors in seven impacted canines, and on both in six impacted canines and on the adjacent premolars in two cases.

**Table 4: Comparison of cuspal tip distance between axial and sagittal views**

View	Mean	Standard deviation	SE of mean	Mean difference	t	P-value
Axial	7.77	4.55	0.83			
Sagittal	10.73	5.02	0.92	-2.960	-2.395	0.020*

SE: Standard error. \*Denotes significant difference. Higher mean cuspal tip distance was recorded in sagittal view compared to axial view and the difference between them was found to be statistically significant ( $P < 0.05$ )

**Table 5: Comparison of alveolus width between axial and sagittal views**

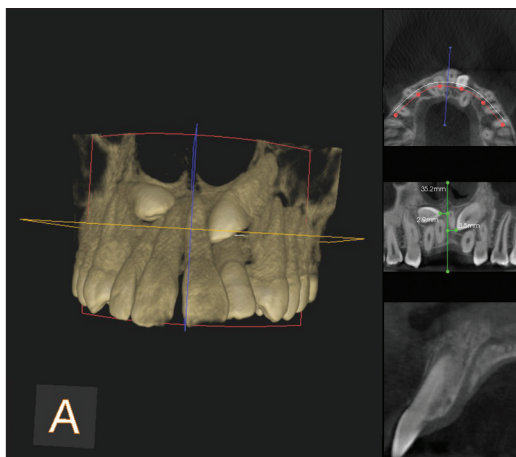
View	Mean	Standard deviation	SE of mean	Mean difference	t	P-value
Axial	0.98	0.46	0.08			
Sagittal	1.37	0.40	0.07	-0.390	-3.523	0.001*

SE: Standard error. \*Denotes significant difference. Higher mean alveolus width was recorded in sagittal view compared to axial view and the difference between them was found to be statistically significant ( $P < 0.05$ )

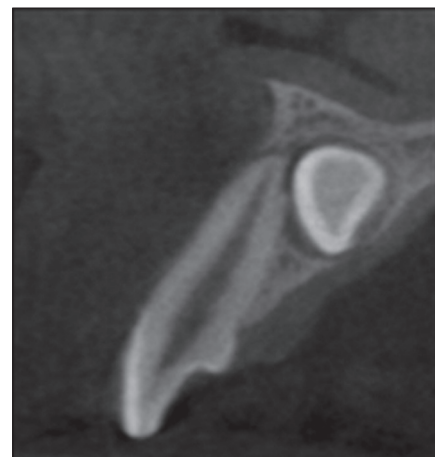
**Table 6: Association between resorption and proximity of adjacent teeth**

Resorption	Touch		No touch		Total	$\chi^2$	P-value
	n	%	n	%			
No resorption	0	0	3	21	3		
Mild	1	6	9	64	10		
Moderate	11	69	2	14	13	19.584	<0.001*
Severe	4	25	0	0	4		
Total	16	100	14	100	30		

\*Denotes significant association. Higher no. of samples with touch proximity had moderate resorption; whereas, higher no. of samples with no touch proximity had mild resorption. The association between resorption and proximity was found to be statistically significant ( $P < 0.001$ )



**Figure 6:** 3D reconstructed image with clear demarcation of cuspal tip of impacted canines in anteroposterior direction



**Figure 7:** Sagittal view showing the resorption of root of the adjacent incisor at the apical third

## Discussion

The prevalence of maxillary canine impaction appears to vary within a range of 0.9-3.0%, depending on the population examined. Females are reported to be more commonly affected.<sup>[1,4,10,11]</sup> Studies have shown that 2D imaging with panoramic X-rays is not a reliable method for localization of impacted canines.<sup>[12,13]</sup> For accurate location, the position of the canine must be measured in three dimensions. CBCT allows description in all three planes of space.<sup>[4,13]</sup>

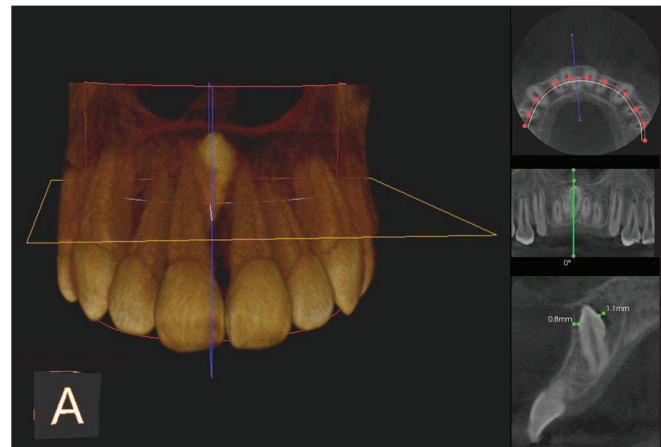
Previously, spatial relationship of the impacted canines was described using 2D images obtained from CBCT.<sup>[14]</sup> However, it has been shown that it is feasible to quantify 3D tooth displacements from CBCT data with sufficient accuracy, by Chen *et al.*<sup>[6]</sup> 3D volumetric imaging might provide information for improved diagnosis and treatment plans, and ultimately result in more successful treatment outcomes and improved patient care.<sup>[15,16]</sup> Kau *et al.*,<sup>[17]</sup> stated that in complex orthodontic cases, such as in canine impactions and cleft lip and palate, 3D imaging is mandatory and CBCT is the imaging of choice.

CBCT, which provides a lower-dose, lower-cost alternative to conventional CT, is being used with increasing frequency in the practice of orthodontics and oral and maxillofacial radiology. Based on the diagnostic requirements, the field of view (FOV), mA, and kV can be altered to reduce the radiation dosage.<sup>[8,13]</sup>

The etiology of impacted canine remains unclear. Adjacent peg-shaped or missing lateral incisors have been suggested to contribute to the palatally impacted canines by not providing proper guidance to the canine during its eruption. However, Peck *et al.*,<sup>[14]</sup> have stated that the etiology of palatally impacted canines is genetic in origin. The etiology of labially impacted canines is due to an inadequate arch space.<sup>[10,14]</sup>

Angular and linear measurements indicate that maxillary canine impaction varies greatly, the cuspal tip distance of the impacted canine to the occlusal plane was significantly increased in the sagittal view, in conditions like horizontal impaction the value was found to be least in the axial view. Whereas, the readings were of negative when the canine tip was inverted towards the anterior nasal spine [Figure 8].

When comparing the angulation, there was no statistical difference between views. The angle varied in horizontal impaction, since it was inappropriate to obtain the long axis of the impacted canine in sagittal view. Hence, the



**Figure 8:** Three-dimensional reconstructed image of a patient showing the orientation of the cuspal tip directed towards the anterior nasal spine

axial view is the choice in such instances to orient the long axis to the occlusal plane [Figure 4].

The alveolus width of the impacted canines is increased in sagittal view with a mean difference of  $-0.390$  mm when compared to the axial views. The width was greater when the canine was palatally impacted and towards the midsagittal plane [Figure 3], thus the readings from different views can guide the operator (surgeon) for better surgical approach to create most appropriate window or exposure of the impacted canine for a suitable placement of an orthodontic auxiliary/attachment.

The mechanism of root resorption following maleruption and the factors involved in the process are not clear. Most authors have stressed the role of physical pressure due to the migration of the maxillary canine.<sup>[2]</sup> Accordingly in this study, 11 of 13 resorbed lateral incisors and five out of seven resorbed central incisors were in close contact with the impacted canines, indicating that incisor resorption was significantly correlated with contact between the incisor and impacted canine. This finding was consistent with previous studies by Ericson and Kuroi.<sup>[2,3]</sup>

The proper treatment of impacted maxillary canines depends on patient age and cosurgical procedure, general oral health, type of impaction, presence of spacing and crowding, and associated complications such as resorption of adjacent teeth and cystic degeneration.<sup>[2,3,10]</sup>

Treatment alternatives include interceptive treatment, surgical exposure and orthodontic alignment, autotransplantation, or even extraction of the impacted canine.<sup>[18]</sup> For patients 10-13 years of age, and under conditions where adequate space exists, Ericson and Kuroi<sup>[2]</sup> recommend the extraction of the deciduous canine as the treatment of choice to correct palatally impacted canines.

Horizontal and inverted impactions represent a severe vertically abnormal path of eruption; therefore, extraction of the canine is in most cases desirable, or otherwise the canines may be left *in situ*, provided that they are far away from the normal dentition.<sup>[7,11,16]</sup>

For those impactions that should be removed or exposed, the 3D orientation in different planes/views provided by CBCT can assist surgeons in choosing the appropriate surgical approach, identifying the tooth that should be extracted, and reducing the amount of surgical trauma on the adjacent hard and soft tissues. And also assist in reducing the biomechanics involved during canine retraction, when they are favorably impacted.<sup>[4]</sup>

## Conclusion

The position of impacted maxillary canines varied greatly, both in the vertical and horizontal inclination/angulation. In the above study, axial view showed a significant difference in the alveolus width and cuspal tip distances in horizontal and mesiopalatally impacted canines. Though we could not find much statistical difference between both views in terms of angulation, but higher mean angulation was recorded in sagittal view compared to axial view. Hence, with this study we conclude that axial view was much reliable compared to sagittal and other views depending upon the type of impaction.<sup>[4]</sup>

## Acknowledgment

We sincerely thank Mr. Tejasvi Venkatesh Murthy (statistician) for his expert assistance and guidance.

## References

1. Grover PS, Lorton L. The incidence of unerupted permanent teeth and related clinical cases. *Oral Surg Oral Med Oral Pathol* 1985;59:420-5.
2. Ericson S, Kurol PJ. Resorption of incisors after ectopic eruption of maxillary canines: A CT study. *Angle Orthod* 2000;70:415-23.
3. Ericson S, Kurol J. Resorption of maxillary lateral incisors caused by ectopic eruption of the canines. A clinical and radiographic analysis of predisposing factors. *Am J Orthod Dentofacial Orthop* 1988;94:503-13.
4. Walker L, Enciso R, Mah J. Three-dimensional localization of maxillary canines with cone-beam computed tomography. *Am J Orthod Dentofacial Orthop* 2005;128:418-23.
5. Chaushu S, Chaushu G, Becker A. The role of digital volume tomography in the imaging of impacted teeth. *World J Orthod* 2004;5:120-32.
6. Chen J, Li S, Fang S. Quantification of tooth displacement from cone-beam computed tomography images. *Am J Orthod Dentofac Orthop* 2009;136:393-400.
7. Ferguson JW, Pitt SK. Management of unerupted maxillary canines where no orthodontic treatment is planned; A survey of UK consultant opinion. *J Orthod* 2004;31:28-33.
8. Gibbs SJ. Effective dose equivalent and effective dose: Comparison for common projections in oral and maxillofacial radiology. *Oral Surg Oral Med Oral Pathol Oral Radiol Endod* 2000;90:538-45.
9. Oliver RG, Mannion JE, Robinson JM. Morphology of the maxillary lateral incisor in cases of unilateral impaction of maxillary canine. *Br J Orthod* 1989;16:9-16.
10. Jacobs SG. The impacted maxillary canine. Further observations on aetiology, radiographic localization, prevention/interception of impaction, and when to suspect impaction. *Aust Dent J* 1996;41:310-6.
11. McSherry PF. The ectopic maxillary canine: A review. *Br J Orthod* 1998;25:209-16.
12. Nagpal A, Pai KM, Setty S, Sharma G. Localization of impacted maxillary canines using panoramic radiography. *J Oral Sci* 2009;51:37-45.
13. Mason C, Papadakou P, Roberts GJ. The radiographic localization of impacted canines: A comparison of methods. *Eur J Orthod* 2001;23:25-34.
14. Peck S, Peck L, Kataja M. The palatally displaced canine as a dental anomaly of genetic origin. *Angle Orthod* 1994;64:249-56.
15. Becker A, Chaushu S. Success rate and duration of orthodontic treatment for adult patients with palatally impacted maxillary canines. *Am J Orthod Dentofacial Orthop* 2003;124:509-14.
16. Peng CL, Su YY, Lee SY. Unilateral horizontally impacted maxillary canine and first premolar treatment with a double archwire technique. *Angle Orthod* 2006;76:502-9.
17. Kau CH, Bozic M, English J, Lee R, Bussa H, Ellis RK. Cone-beam computed tomography of the maxillofacial region--an update. *Int J Med Robot* 2009;5:366-80.
18. Kokich VG. Surgical and orthodontic management of impacted maxillary canines. *Am J Orthod Dentofacial Orthop* 2004;126:278-83.

**How to cite this article:** Uday NM, Kamath P, Kumar VA, Kumar AB, Scindhia R, Raghuraj MB, Rozario J. Comparison of axial and sagittal views for angulation, cuspal tip distance, and alveolus width in maxillary impacted canines using CBCT. *J Orthod Res* 2014;2:21-6.

**Source of Support:** Nil. **Conflict of Interest:** No.