

Triorchidism: A Rare Genitourinary Abnormality

Trupti Tonape, Gurjit Singh, P. Koushik, Trinath Tumepalli

Department of Surgery, Dr. D. Y. Patil Medical College,
Pimpri, Pune, India

INTRODUCTION

Polyorchidism is an extremely rare congenital anomaly of the urogenital system which refers to the presence of more than two testicles.^[1] Blasius recorded the first case of triorchidism at a routine autopsy in 1670.^[2] There have been 178 reports (198 cases) of polyorchidism in the English literature till date.^[3] Majority of patients are asymptomatic however some may present as painless inguinal or scrotal masses, undescended testis, and rarely, torsion of the supernumerary testis.^[4]

CASE REPORT

A 2-years-old child was brought with bilateral undescended testis with normal milestones. Ultrasonography of scrotum, abdomen and pelvis showed both the testes to be in inguinal canal. Child was posted for bilateral orchidopexy. Intra-operatively, on left side – there were two testes, the larger one measuring 2×1 cm, smaller one measuring 1×0.5 cm. Both testes had its own epididymis and both epididymis drained into one vas deferens at the level of internal ring (Leung III class) [Figure 1].

The two left sided testes were subjected to Fine needle aspiration cytology (FNAC) which confirmed presence of viable testicular tissue. Orchidopexy of both the testes was performed. Right testis measured 3×2 cm located in inguinal region was also subjected to orchidopexy. Child is under close follow up for the past 1 year and is normal.

Access this article online

Quick Response Code:



Website:

www.jstcr.org

DOI:

10.4103/2006-8808.110262

Address for correspondence: Dr. P. Koushik,
Department of Surgery, Dr. D. Y. Patil Medical College,
Pimpri, Pune, India. E-mail: koushik_reddy_doc@yahoo.co.in

ABSTRACT

Polyorchidism is an extremely rare congenital anomaly which refers to the presence of more than two testicles. There are very few reports of triorchidism in a 2 year old child. Polyorchidism is usually discovered incidentally. The most common anomalies associated with polyorchidism are inguinal hernia (30%), maldescended testis (15% to 30%), testicular torsion (13%) and hydrocele (9%). A 2-year-old child was brought with bilateral undescended testis with normal milestones. Ultrasonography of scrotum and abdomen showed both the testes to be in inguinal canal. Intra-operatively, on left side – there were two testes, which belonged to Leung III class and one testis on right side. Management of polyorchidism is still controversial. The management of polyorchidism will depend upon the location, size and anatomical organisation of the testicular drainage system and the age of the patient.

Key words: Fine needle aspiration cytology, follow up, triorchidism

DISCUSSION

The first proven case of extra testis was reported by Lane in 1895.^[1] About 50% of the cases are detected between 15 and 25 years of age.^[4] Very few cases of triorchidism have been reported in a child less than or equal to 2 years till date, making our case a very rare presentation. The most common presentation of polyorchidism is triorchidism and the left side is predominantly affected as in our case.^[5]

Some believe that the condition should be confirmed by histological examination.^[3]

Majority of supernumerary testes are located in the scrotal region (66%) followed by inguinal (23%) as in our case and abdominal (9%) positions.^[2]

In a normal embryo, at about 6 weeks of embryonic life, the primordial testis develops from the primitive genital ridge medial to the mesonephric ducts. At about 8 weeks, the primordial testis takes shape, and the epididymis and vas deferens arise from the mesonephric (wolffian) duct.^[6] The exact mechanism for occurrence of polyorchidism is not known, but longitudinal or transverse division of the genital ridge, possibly by development of peritoneal bands, has been proposed.^[6-8] No single theory can explain all types of polyorchidism.^[2] There are a number of classifications for polyorchidism.

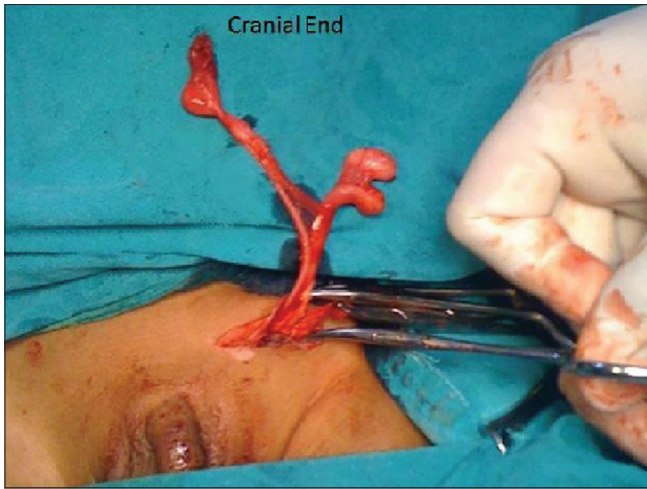


Figure 1: Operative photograph showing two testis on left side with their respective epididymis draining into one vas



Figure 2: Type-I: Supernumerary testis lacks an epididymis or vas and has got no attachment to the usual testis. (Division of genital ridge only)



Figure 3: Type-II: The supernumerary testis drains into epididymis of usual testis and they share a common vas. (Division of genital ridge occurs in the region where the primordial gonads are attached to the metanephric ducts, although the mesonephros and metanephric ducts are not divided, i.e., incomplete division)



Figure 4: Type-III: The supernumerary testis has its own epididymis and both epididymis of the ipsilateral testes draining into one vas. (Complete transverse division of mesonephros as well as genital ridge)

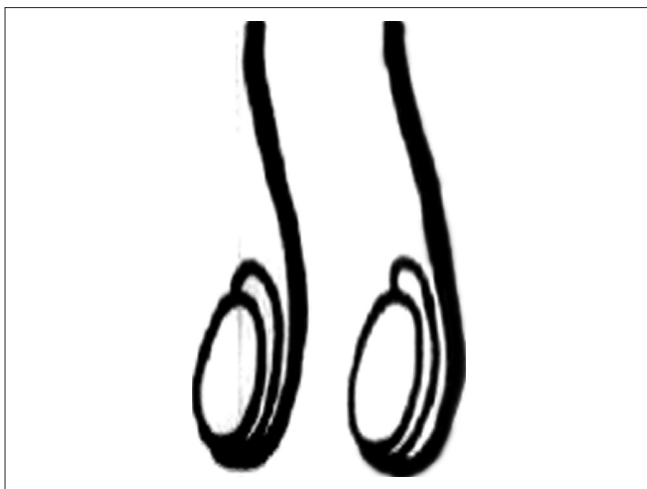


Figure 5: Type-IV: Complete duplication of testes, epididymis and vas. (Vertical division of genital ridge and mesonephros)

Leung described the first anatomical classification which was based on the possible embryological variations.^[5] [Figures 2-5]. According to Leung, Type II is the most common type and together with Type III they comprise 90% of cases of polyorchidism.^[5] Singer *et al.* suggested an anatomical as well as functional classification.^[8]

Polyorchidism seldom presents by itself, and is usually discovered incidentally as in our case. The most common anomalies associated with polyorchidism are inguinal hernia (30%), maldescended testis (15% to 30%) as in our case, testicular torsion (13%) hydrocele (9%), varicocele (<1%), hypospadias (<1%), anomalous urogenital union (<1%), and malignancy (<1%).^[9]

Supernumerary testes are usually removed despite the

fact that there is poor evidence in literature supporting this.^[10]

Few authors who proposed a conservative approach argue that infertility is a common finding in patients with polyorchidism and preserving a potentially functional supernumerary testis to improve the capacity for spermatogenesis is essential even if they are found to be smaller or in ectopic locations.^[11] It is suggested that all gonadal tissue should be left in the scrotum to maximize potential fertility.^[12] This potential benefit is weighed against a 4% to 7% risk of malignancy in these patients. Magnetic resonance imaging has been suggested as a safe and sensitive method for long-term surveillance of patients with polyorchidism. Although this may not be cost effective, it gives the option of preserving a functioning supernumerary testicle found incidentally if there is doubt about its long-term outcome.^[13]

Others argue that the majority of accessory testes have histologically reduced or absent spermatogenesis and propose that the increased risk of malignancy warrants removal of the supernumerary testis, particularly if it is non-viable, undescended or ectopically located.^[14]

Polyorchidism is usually identified during orchidopexy as in our case and during repair of indirect inguinal hernia.

FNAC was done to confirm that it is a testicular tissue and to check for the viability. It would give an excellent idea of spermatogenic potential of that testis, regardless of age^[15] and had been carried out in our case. Biopsy was not done as the size of the testis was very small. Testicular biopsy is rarely indicated in paediatric population.^[16]

Follow up of these patients will be once a month for first 3 months then every 6 months for next 2 years, later every 2 years up to adolescence by palpating the testis and ultrasonography. During early adulthood it will be carried out by palpation, ultrasonography, semen analysis, serum testosterone and follicle stimulating hormone levels and during late adulthood follow up will be done by ultrasonography for malignancy every 2 years.

CONCLUSION

Polyorchidism is a rare genitourinary abnormality and its management is still controversial. The management of polyorchidism will depend upon the location, size and anatomical organisation of the testicular drainage system and the age of the patient. We suggest that FNAC being the least traumatic but equally reliable modality in confirming the condition should replace biopsy intra-operatively when polyorchidism is found incidentally.

REFERENCES

1. Lane A. A case of supernumerary testis. *Trans Clin Soc Lond* 1895;28:59.
2. Bergholz R, Wenke K. Polyorchidism: A meta-analysis. *J Urol* 2009;182:2422-7.
3. Kheirandish P, Chingewundoh F. An unusual case of triorchidism. *JRSM Short Rep* 2010;1:55.
4. Kharrazi SM, Rahmani MR, Sakipour M, Khoob S. Polyorchidism: A case report and review of literature. *Urol J* 2006;3:180-3.
5. Kundu AK, Deb D, Pradhan P, Ghosh G, Chakrabarty S. Triorchidism: An incidental finding and review of literature. *J Anat Soc India* 2001;50:37-9.
6. Wolf B, Youngson GG. Polyorchidism. *Pediatr Surg Int* 1998;13:65-6.
7. Leung AK. Polyorchidism. *Am Fam Physician* 1988;38:153-6.
8. Singer BR, Donaldson JG, Jackson DS. Polyorchidism: Functional classification and management strategy. *Urology* 1992;39:384-8.
9. Sharma AK, Mathur P. Polyorchidism. *Pediatr Surg Int* 1994;9:531.
10. Khedis M, Nohra J, Dierickx L, Walschaerts M, Soulié M, Thonneau PF, et al. Polyorchidism: Presentation of 2 cases, review of the literature and a new management strategy. *Urol Int* 2008;80:98-101.
11. Mathur P, Prabhu K, Khamesra HL. Polyorchidism revisited. *Pediatr Surg Int* 2002;18:449-50.
12. Snow BW, Tarry WF, Duckett JW. Polyorchidism: An unusual case. *J Urol* 1985;133:483.
13. Bhogal RH, Palit A, Prasad KK. Conservative management of polyorchidism in a young man: A case report and review of literature. *Pediatr Surg Int* 2007;23:689-91.
14. Scott KW. A case of polyorchidism with testicular teratoma. *J Urol* 1980;124:930-1.
15. Singh JP, Chaturvedi NK, Chawla R. A new approach in evaluation of fertility in surgically treated cryptorchids. *Acta Eur Fertil* 1987;18:321-7.
16. Beiko D, MacNeily AE. Torsion of bilobed testis and biopsy-proven ipsilateral supernumerary testis in an adolescent. *CUAJ* 2010;4:67-70.

How to cite this article: Tonape T, Singh G, Koushik P, Tumepalli T. Triorchidism: A Rare Genitourinary Abnormality. *J Surg Tech Case Report* 2012;4:126-8.

Source of Support: Nil, **Conflict of Interest:** None declared.