

# Dorsal Slit-Sleeve Technique for Male Circumcision

**Christopher Suiye Lukong**

*Department of Surgery, Usmanu Danfodiyo University  
Teaching Hospital Sokoto, Nigeria*

## INTRODUCTION

Circumcision is a common surgical operation in pediatric surgical practice.<sup>[1,2]</sup> It is one of the most ancient surgical procedures and has remained controversial in several aspects.<sup>[3,4]</sup> There are therefore several methods and each of the methods has its merits and demerits.<sup>[5,6]</sup> The basic principle in circumcision is to ensure that safety and morbidity should be kept to the barest minimum, no matter what technique is employed.

There are several conventional open techniques for circumcision, namely the dorsal slit, the sleeve, and the quillotine.<sup>[6]</sup> Circumcision is also performed with the use of devices such as the plastibell, the mogan clamp, or the gomco clamp. A combination of the dorsal slit and the sleeve technique is possible and was consistently used in our center. We term this method, the dorsal slit-sleeve technique.

This article describes the dorsal slit-sleeve method of male circumcision. The merits and demerits of this technique are described, based on our experience.

## PREOPERATIVE PREPARATION

### Selection criteria

1. Neonates, infants, and children with intact prepuce

| Access this article online  |                                  |
|---|----------------------------------|
| Quick Response Code:  | Website:<br>www.jstcr.org        |
|  | DOI:<br>10.4103/2006-8808.110261 |

**Address for correspondence:** Dr. Christopher Suiye Lukong,  
Department of Surgery, Usmanu Danfodiyo University  
Teaching Hospital, Sokoto, Nigeria.  
E-mail: lukongchris@gmail.com

## ABSTRACT

Male circumcision is a commonly performed surgical procedure. There are several techniques of circumcision. The device methods are thought to have lower complication rates when compared to the open methods. The devices for circumcision may not be readily available or may be expensive. The open methods are therefore still commonly used in this setting. The dorsal slit-sleeve technique combines strategies from two open methods. The technique is described, together with its merit and demerits. This technique is feasible, safe, and the general outcome is good.

**Key words:** Circumcision, device, dorsal slit, sleeve, technique

1. requiring circumcision for religious or cultural reasons.
2. Medical indications for circumcision such as phimosis, paraphimosis, and balanoprophitis.

### Exclusion criteria

1. Hypospadias
2. Buried penis
3. Bleeding disorders

The child should be clinically healthy and there should be no features or family history of bleeding disorder.

## SURGICAL TECHNIQUE

### Anesthesia

This procedure is done under general anesthesia, combined with field block of the penis using plain lignocaine (0.25%). Lignocaine with adrenalin must be avoided owing to its ischemic effects on the glans penis.

### Position

The patient is placed supine, with the legs astride to expose the penis.

### Cleaning and draping

The penis and the immediate surrounding area is prepped with povidone-iodine and draped with a perineal sheet.

## INTRAOPERATIVE STEPS OF THE DORSAL SLIT-SLEEVE TECHNIQUE

1. Two artery forceps are applied on either side of the preputial opening. A curved artery forcep lubricated with lignocaine gel, is introduced to dilate the opening and separate the adhesions between the glans penis and the prepuce [Figure 1]. The artery forcep is turned upwards and away from the urethral meatus. This maneuver avoids the risk of injury to the urethral meatus
2. The prepuce is everted. This enables the smegma to be cleaned and any adhesions to be separated. The prepuce is freed right to the corona [Figure 2]. At this stage a circumferential knife incision mark is made on the inner preputial skin leaving a sleeve of 0.25-0.5 cm proximal to the corona
3. The prepuce is returned over the glans penis. Two artery forceps are applied on either side of the prepuce. With slight traction on the prepuce another circumferential knife mark incision is made over the penile skin just proximal to the corona [Figure 3]
4. A dorsal slit is made on the preputial skin down to penile skin mark, after crushing with an artery forcep for 3-5 minutes [Figures 4 and 5]. The crushing helps to reduce bleeding. The penile skin incision is then deepened to the level of buck's fascia. The preputial skin is resected leaving a 0.5 cm sleeve proximal to the corona. Caution is exercised at this stage to avoid injury to the urethra. The ventral part of the penile skin incision is deepened only to the level of dartos fascia initially. Then bucks fascia is carefully divided under clear vision. This way injury to the urethra is avoided. Hemostasis is secured by ligating the bleeding vessels, starting with the frenular artery
5. The proximal penile skin is then sutured to the coronal preputial sleeve using 5/0 chromic catgut or 5/0 vicryl [Figure 6]. The sutures at the frenular area ventrally are placed laterally to avoid injury to the urethra. A dressing of suffra tulle gauze is placed round the coronal suture line if there is still oozing of blood; otherwise the wound is left open.

## POSTOPERATIVE CARE

The field block with plain lignocaine gives good postoperative analgesia. This is complimented with paracetamol syrup or suppository, which is given for 72 hours.

The child is commenced on breast milk as soon as full consciousness is regained.

The dressing is removed at home after 48 hours and vaseline is applied to the wound daily for one week. The patient is followed-up after 1, 2, and 6 weeks.

## DISCUSSION

The dorsal slit method requires crushing and division of the inner and the outer preputial layers dorsally. The slit is extended to the corona. This enables the prepuce to be freed completely and excised, under direct vision.

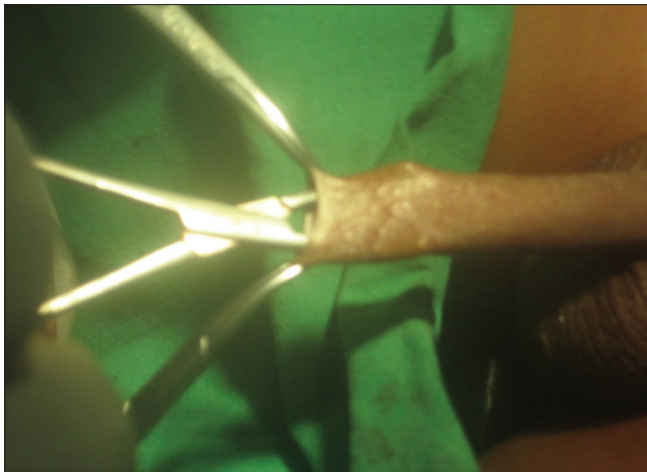
The sleeve method involves excision of the two preputial layers under direct vision, starting with the outer layer to allow for hemostasis by ligating the bleeding vessels.

The dorsal slit-sleeve technique was effectively used in our center with good outcome. So far we have circumcised 100 neonates with this method over a 4-year period. There was one (1.0%) neonate who had reactionary hemorrhage and this was addressed appropriately. The method is safe, effective and dissection of tissues is done under direct vision. This method has an advantage in that any injury caused can be identified immediately and addressed intraoperatively. The crushing of the preputial skin before the dorsal slit, reduces hemorrhage. It gives satisfactory cosmetic outlook and the risk of redundant preputial skin is minimal. The disadvantage of the method is that, it has a learning curve. It is fraught with more complications in the hands of nonexperts. This fact collaborates with complications noted by other authors using the device methods.<sup>[7-13]</sup>

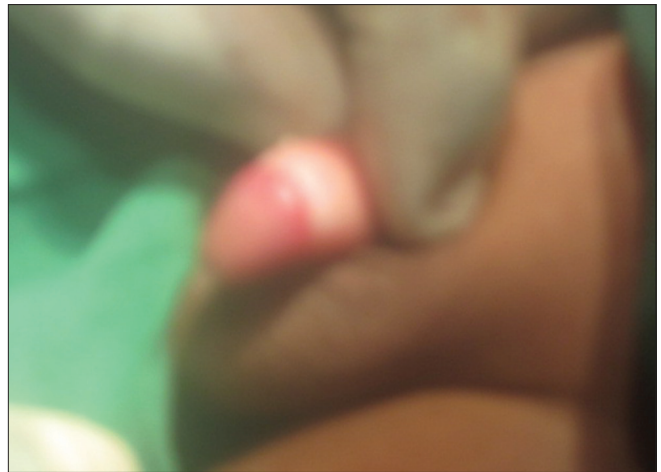The device methods of circumcision such as the plastibell, the mogen clamp, and the gomco clamp was meant to avoid glanular and urethra injury. Unfortunately these injuries still do occur with these methods, especially with the nonexperts.<sup>[2,9,11,12]</sup>

The ultimate aim of any method of circumcision is that it should be safe and complication free. It should therefore be done by those trained to do it. Where nonexperts are to be involved, they should be trained, certified, and be monitored regularly.

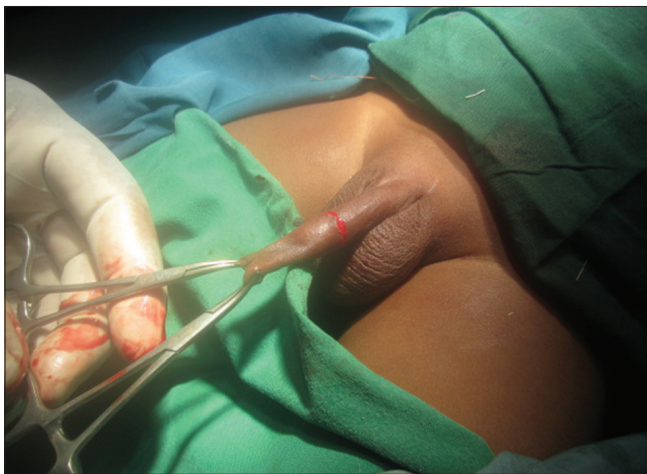Circumcision is often considered as a minor procedure and most often delegated to junior surgical staff or trainee. The complications from circumcision could sometimes be more when compared with more complex urological procedures. Therefore circumcision should be performed by experts and should not be left to the junior staff or trainee.



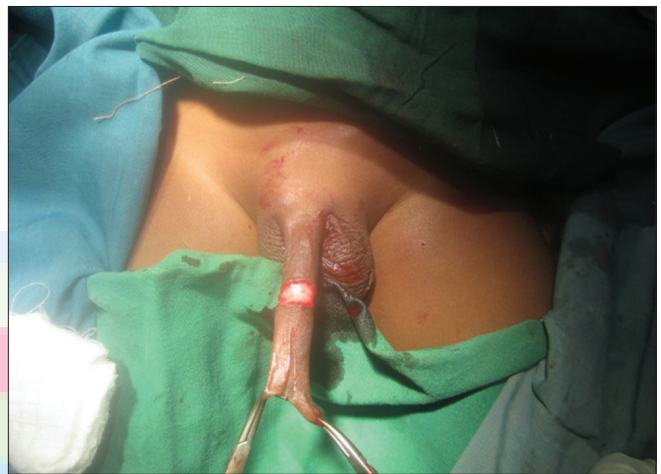**Figure 1:** Dilating the preputial orifice and separating adhesions



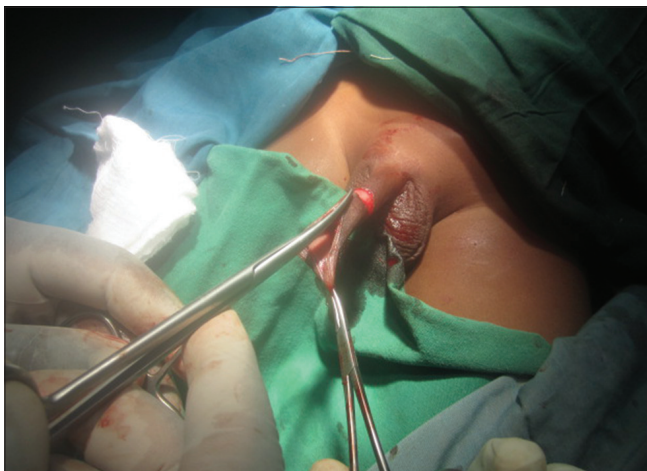**Figure 2:** Glans penis freed and prepuce everted



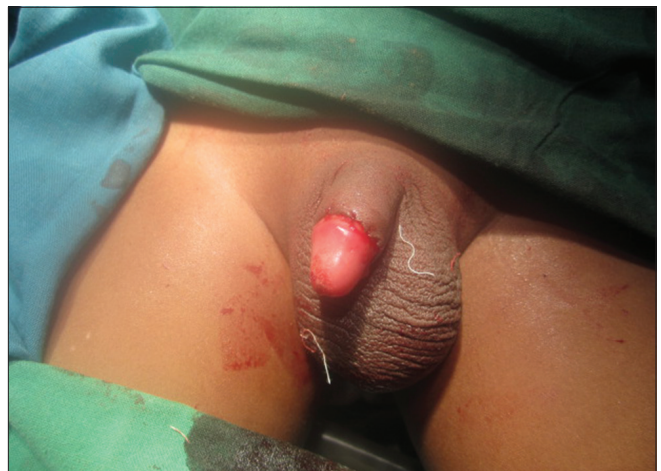**Figure 3:** Circumferential knife skin mark



**Figure 4:** Crushed prepuce dorsally



**Figure 5:** Dorsal slit



**Figure 6:** Circumcised penis

## REFERENCES

1. Hyns CF, Kriegler JN. Circumcision. In: Schill WB, Comhaire FR, Hargreave TB, editors. *Andrology for the clinician*. Springer-Verlag; Berlin; 2006. p. 203-12.
2. Task force on circumcision. Male circumcision. *Pediatrics* 2012;130:e756-85.
3. Lukong CS. Circumcision: Controversies and prospects. *J Surg Tech Case Rep* 2011;3:65-6.
4. Pinto K. Circumcision controversies. *Pediatr Clin North Am* 2012;59:977-86.
5. Holman J, Lewis E, Ringlar R. Neonatal circumcision techniques. *Am Fam Physician* 1995;52:511-8.



6. Harahap M, Siregar AS. Circumcision: A review and a new technique. *J Dermatol Surg Oncol* 1988;14:383-6.
7. Krill AJ, Palmer LS, Palmer JS. Complications of circumcision. *ScientificWorldJournal* 2011;11:2458-68.
8. Williams N, Kapila L. Complications of circumcision. *Br J Surg* 1993;80:1231-6.
9. Bode CO, Ikhisemogie S, Ademuyiwa AO. Penile injuries from proximal migration of plastibell circumcision ring. *J Pediatr Urol* 2010;6:23-7.
10. Weiss HA, Larke N, Halperin D, Schenker I. Complications of circumcision in male neonates, infants and children: A systemic review. *BMC Urol* 2010;10:2.
11. Mousavi SA, Salehifar E. Circumcision complications associated with the plastibell device and conventional dissection surgery: Trial of 586 infants of ages up to 12 months. *Adv Urol* 2008;60:6123.
12. Peleg D, Steiner A. The Gomco circumcision: Common problems and solutions. *Am Fam Physician* 1998;58:891-8.
13. Kidger EA, Haeder N, Qazi A. Acquired phimosis after plastibell circumcision: A preventable consequence. *Ann R Coll Surg Engl* 2012;94:186-8.

**How to cite this article:** Lukong CS. Dorsal Slit-Sleeve Technique for Male Circumcision. *J Surg Tech Case Report* 2012;4:94-7.

**Source of Support:** Nil, **Conflict of Interest:** None declared.

