

Techniques of Male Circumcision

Abdullahi Abdulwahab-Ahmed, Ismaila A. Mungadi

Department of Surgery, Usmanu Danfodiyo University
Teaching Hospital Sokoto, Nigeria

INTRODUCTION

Circumcision is the surgical removal of the prepuce (foreskin) either in whole or in part. Religion, cultural, medical, and recently public health reasons^[1,2] are known to be the major indications of the procedure. Usually, it is done in neonatal period but can be performed at any age. To maximize its health benefits,^[1,2] to reduce procedural risks and cost,^[2-6] however, it is advocated to be offered in neonatal period. Surgical approaches to circumcision are extremely varied.^[7]

About 25-33% of the total world male population is circumcised.^[8-11] In the US, an average of a million newborn males are circumcised yearly.^[12] Circumcision rate in US is as high as 70%, while in Britain it is 6%.^[12] In Nigeria, circumcision rate is estimated to be 87%.^[8]

Circumcision is arguably the oldest surgical procedure in history.^[13] Religious circumcision is practiced by the Jews; religious and cultural circumcision is also practiced by Muslims, Black Africans, Australian aborigines, and other ethnic groups in different parts of the world.^[12] In Western societies, circumcision is mostly performed for medical reasons, the most common of which is phimosis.^[7,12,13] Other medical indications are paraphimosis, balanitis (inflammation of the prepuce), posthitis (inflammation of the glans), localized condylomata acuminata, and localized carcinoma.^[13-15]

Access this article online

Quick Response Code:



Website:

www.jstcr.org

DOI:

10.4103/2006-8808.118588

Address for correspondence: Dr. Abdullahi Abdulwahab-Ahmed,
Department of Surgery, Usmanu Danfodiyo University
Teaching Hospital (UDUTH), Sokoto, Nigeria.
E-mail: abdulneuro@yahoo.com

ABSTRACT

Male circumcision is a controversial subject in surgical practice. There are, however, clear surgical indications of this procedure. The American Academy of Pediatrics (AAP) recommends newborn male circumcision for its preventive and public health benefits that has been shown to outweigh the risks of newborn male circumcision. Many surgical techniques have been reported. The present review discusses some of these techniques with their merits and drawbacks. This is an attempt to inform the reader on surgical aspects of male circumcision aiding in making appropriate choice of a technique to offer patients. Pubmed search was done with the keywords: Circumcision, technique, complications, and history. Relevant articles on techniques of circumcision were selected for the review. Various methods of circumcision including several devices are in use for male circumcision. These methods can be grouped into three: Shield and clamp, dorsal slit, and excision. The device methods appear favored in the pediatric circumcision while the risk of complications increases with increasing age of the patient at surgery.

Key words: Complication, dorsal slit, device, excision, male circumcision, public health benefit, technique

Currently, the public health benefits of male circumcision are topic of interest particularly as regards human immunodeficiency virus (HIV) prevention.^[1,2] It is shown to reduce the risk of transmission of HIV infection in heterosexuals.^[16,17] Its benefits in reducing the risk of urinary tract infections in boys and reduction in transmission of other sexually transmitted infections are well documented.^[1-6]

Contraindications of this procedure include congenital abnormalities of the phallus such as hypospadias, epispadias, megalourethra, webbed penis, and any other condition in which prior circumcision renders treatment more difficult. Others are prematurity, bleeding problems, myelomeningocele, and anorectal anomaly.^[12,14]

Embryology

Developmentally, during the third month of intrauterine life (65 mm fetus), a fold of skin develops at the base of the glans penis. This fold of skin grows distally from the glans penis and eventually becomes the prepuce. The dorsal aspect of the fold grows more rapidly than the

ventral aspect, initially only the dorsum of the glans penis is covered by this fold.^[18] As the glanular urethra fuses in the midline, it carries the ventral prepuce along with it. This ventral fusion of the prepuce is marked by the frenulum. Preputial formation is usually complete by the fifth month of intrauterine life (100 mm fetus). The inner surface of the prepuce and epithelium of the glans, are both stratified squamous epithelium in type, and both fuses together. Later, presumably under the influence of androgens, the squamous cells begin to keratinize and arrange themselves in whorls. The whorled cells then disintegrate so that clefts appear between the prepuce and the glans. These clefts eventually propagate and separate the inner preputial epithelium and the epithelium of the glans from each other. This process of separation is usually incomplete at birth and continues through childhood and sometimes to adult life.^[14,18]

Techniques

The principles of circumcision are asepsis, adequate excision of outer and inner preputial skin layers, hemostasis, protection of the glans and urethra, and cosmesis. The goal of the procedure is to expose the glans sufficient to prevent phimosis or paraphimosis. Circumcision methods can be classified into one of three types or combinations thereof: dorsal slit, shield and clamp, and excision.^[12,14] Many of the methods in use today fall in to one of these major classes. Shield and clamp adopts the use of device to effect circumcision obviating the use of knife in majority of cases. The device method is the commonly used method of circumcision in recent practice.

Anesthesia

The procedure is done under local anesthesia. There are many ways of achieving this: penile ring block, penile dorsal nerve block, and local anesthetic spray jet injector have all been described.^[19-21] While the spray injector procedure requires an appliance that is uncommon and expensive (e.g., No-Needle MadaJet®),^[20] penile dorsal nerve block and the ring penile block can be easily learned and carried out by all.^[19,20]

Penile dorsal nerve block is a safe and appropriate anesthesia technique for circumcision procedure. The aim of the block is to deliver adequate local anesthetic agent at a dose of 1 ml + 0.1 ml/kg body weight around the main trunk of the dorsal nerve of the penis and its ventral branch.^[19] This is easily accessible just below the symphysis pubis deep to the fascia and on either side of the penile suspensory ligament. Care is taken to avoid the midline where dorsal vessels that may be cause of hematoma and

poor nerve block passes.

Shield and clamp

The prototype method in shield and clamp is the Mogen clamp [Figure 1]. In this method, the prepuce is pulled out distal to the glans and a metal shield is slid over the prepuce immediately distal to the glans. A scalpel is used to remove the redundant prepuce distal to the shield. The glans is protected by the shield and the frenulum is not involved in the excision.^[20] The inner preputial layer may then be slit back behind the glans and excised, this ensure full exposure of the glans after healing. No stitching is done, the wound simply being bandaged to achieve hemostasis. The glans and the frenulum are shielded from the knife and thus are off the harm's way. Injury to the glans and urethrocutaneous fistula is uncommon; bleeding is, however, a major concern in this method.

Plastibell®

A plastic bell [Figure 2] with a groove on its back is slipped between the glans and the prepuce, an initial dorsal slit [Figure 3] is usually needed to allow the bell to be placed. The prepuce is pulled slightly forward and suture material is looped around in the groove and tied tightly.^[2,11,20,22] The suture cuts off the blood supply to the prepuce distal to the groove, which withers and drops off in 7-10 days. Glans necrosis and failure of the prepuce to fall-off are the two main complications of this technique. Inappropriate bell size and not tight enough suture over the prepuce are the main cause of these complications. Its main advantage is low risk of bleeding.

Gomco

A metal bell [Figure 4] is placed over the glans after the prepuce is fully retracted. The prepuce is then replaced over it this is facilitated by dorsal slit. A metal plate, with a machined under surface in which the rim of the bell sits, is placed over the bell.^[11,20] The prepuce thus lies between the plate and the bell. A tensioning bar is hooked under a T-shaped piece on the top of the bell and screwed down tight to the metal plate; this traps the foreskin in position. A scalpel is run around the upper surface of the plate to remove the prepuce after adequate strangulation. Hemorrhage is one of the complication here hence the application of hemostatic stitches.^[11,20] Catastrophe resulting in whole penile loss occurs when this procedure is done with diathermy. Its main merit like other shield method is that the glans and the frenulum are protected.

Zhenxi Rings

The prepuce is freed from and retracted over the glans.

Grooved sleeve is passed over the glans to sit just behind the corona. The prepuce is then replaced over this sleeve [Figure 5], the position of the prepuce is adjusted and the nut tightened to hold the prepuce in place. An elastic cord is then wound tightly around the phallus, compressing the prepuce into the groove of the sleeve below it. This constricts the prepuce distally. The glans and frenulum are protected so that the frenulum remains intact. Too tight a sleeve can result in glans necrosis and too loose, one can give poor cosmetic outcome.



Figure 1: Mogen clamp

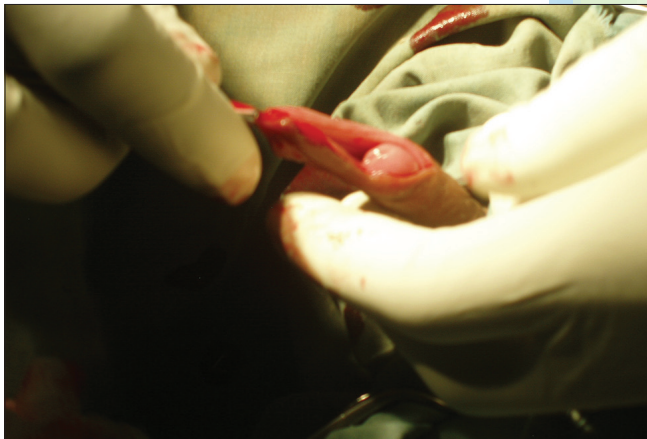

Figure 3: Dorsal slit



Figure 5: Zhenxi ring

Tara Klamp

A Malaysian invention [Figure 6], it is very similar to the plastibell except that instead of having to tie suture material around a groove in the bell, plastic arms lock into place to force two surfaces into tight contact; with the prepuce trapped between them. Its merits and drawbacks are similar to that of plastibell.

SmartKlamp

This works in the same way as the Tara Klamp. By trapping the prepuce between an outer ring and an inner tube, the device cuts off the blood supply to the prepuce. The Tara Klamp is a one piece design with the locking arms at the top. SmartKlamp [Figure 7] consists of separate inner tube and outer locking part with the locking arms at the side. Once the clamp is in place the excess foreskin is removed using the inside of the baseplate as a guide. The glans and




Figure 2: Plastibell

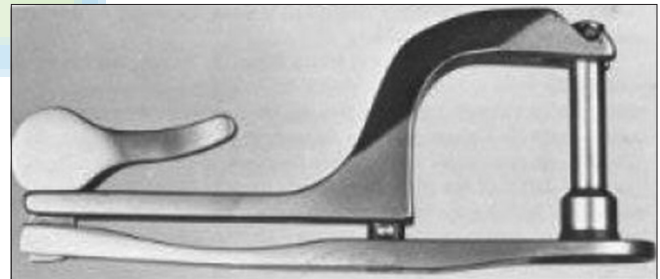


Figure 4: Gomco



Figure 6: Tara klamp

frenulum are thus protected.

Shang Ring®

This is a new Chinese invention consisting of two concentric rings fitting into each other sandwiching the prepuce in between. It is said to be an effective disposable device used for mass circumcision program in HIV prevention. The procedure is easy to learn requiring no special skill.^[21] Shang Ring [Figure 8] major drawback is the lack of a shield for glans protection as such, increases the risks of glans amputation.

PrePex®

This device is unique because of its use in adult male circumcision without the need for anesthesia. It consists of a placement ring, an inner ring, and an elastic ring. The placement ring is a carrier for the elastic ring to facilitate the application of latter during the procedure. The inner ring has a groove on it for the lodgment of the elastic ring. When the device is applied, the prepuce is sandwiched between the inner ring and the elastic ring. The result is ischemic necrosis of the “trapped” prepuce. The PrePex [Figure 9] device is disassembled at about a week after placement and the withered prepuce is bloodlessly severed from the penis. It is said to be safe and effective in mass rollout of adult male circumcision for the prevention of HIV infection.^[2,16,17]

Forceps Guided

In this technique, the prepuce is freed from the glans and pulled out in front of the glans. A pair of stout locking forceps is clamped across it parallel to the corona and immediately in front of the glans. The scalpel is used to remove prepuce flush to the forceps.^[11,20] The glans is protected by the forceps; it is similar to the guillotine method [Figure 10]. This method does not cut the frenulum but it can be removed before or after the circumcision if desired.

Dorsal slit

Dorsal slit [Figure 3] is common to many techniques and occasionally is used alone, especially in the presence of acute inflammation. Dorsal slit prevents both phimosis and paraphimosis. In this procedure, the prepuce is freed from the glans of adhesions and with the aid of artery forceps placed at 10 and 1 o'clock, a 12 o'clock slitting of both layers of the prepuce is done to some few millimeter of the corona.^[11,20] Many of other techniques of circumcisions requires dorsal slit to be carried out first^[22] to widen the outer preputial ring. Usually it is cosmetically unacceptable to carry out dorsal slit alone without excising the prepuce.

Excision

Sleeve Resection: The prepuce is retracted over the glans penis [Figure 11] and a circumferential incision is made around the shaft as far back as the scar line is to be placed, usually distal to the corona. The prepuce is returned to cover the glans and another circumferential incision is made around the shaft at the same position as the first one. A longitudinal cut is made between the two circumferential ones and the strip of skin removed. The free raw edges are then sutured. The frenulum can be included in the main cutting or can be cut separately if desired. The glans and frenulum are not protected as such and care is taken not to injure them.^[11,20]

There are several modifications of the sleeve resection. Bloodless circumcision with the use of bipolar diathermy is described. Some use gauze pack placed between the glans and the inner layer of the prepuce both for tension and hemostasis. Other described the use of an artery forceps to crush the prepuce before excision^[11,20] [Figure 12]. These and many more are aimed to reduce complications of sleeve technique.^[11,20,22]

Laser circumcision: For its many beneficial physical properties as regards precision and sealing of cut surfaces, laser circumcision is possible. There have been some reports of its use in hemophilia patients in Israel. Reports of this in literature are, however, rare.

Complications of circumcision

Bleeding

Excessive bleeding as complication of circumcision in reported cases ranges from 0.1% to 35%. Transfusion for this complication is, however, unusual.^[7,8,12-14] It is more common with the excision method, and when less attention is placed on hemostasis during the procedure.^[11,20]

Concealed penis

In this, an excess of skin is removed from the penile shaft while not enough of the inner preputial layer has been removed. The new preputial orifice is distal to the tip of the penis, the penile shaft is forced into the suprapubic fat, the stenotic preputial ring that results lies at, or just above, the abdominal skin level.^[14]

Phimosis

This results when insufficient outer and inner preputial layers has been removed. Following healing with fibrosis, the new preputial opening is too tight to allow preputial retraction. Repeat circumcision is mandatory to correct this preventable complication.

Skin Bridge

Another adverse result of circumcision is the formation of a skin bridge between the penile shaft and the glans. Smegma may accumulate under the skin bridges. Additionally these bridges may tether the erect penis, with

resultant pain or penile curvature. Treatment is to release the bridges.

Infection

Circumcision wound may become infected, as in any surgical procedure. The incidence of infection in one series of neonatal circumcisions was 0.4%,^[8] while in a series of older boys it was as high as 10%.^[8,12-14]

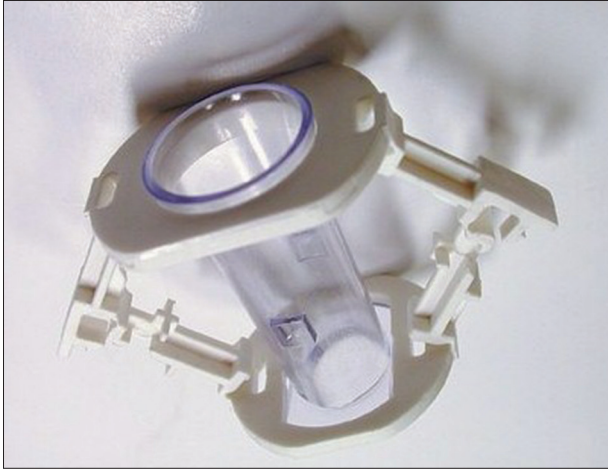


Figure 7: Smartklamp



Figure 8: Shang ring



Figure 9: The PrePex® device



Figure 10: Bone cutter for use in guillotine method

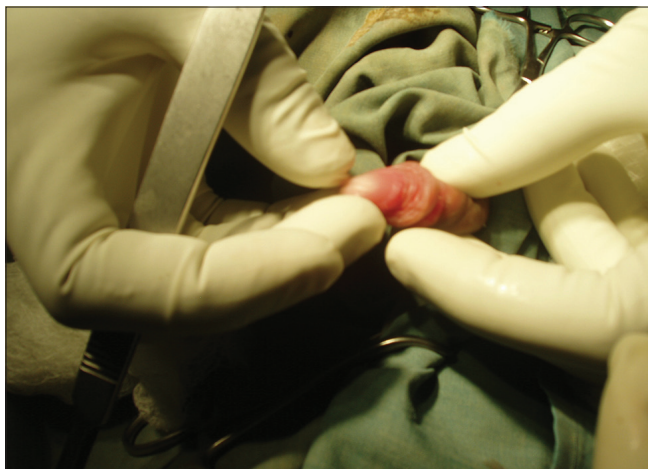

Figure 11: Full preputial retraction

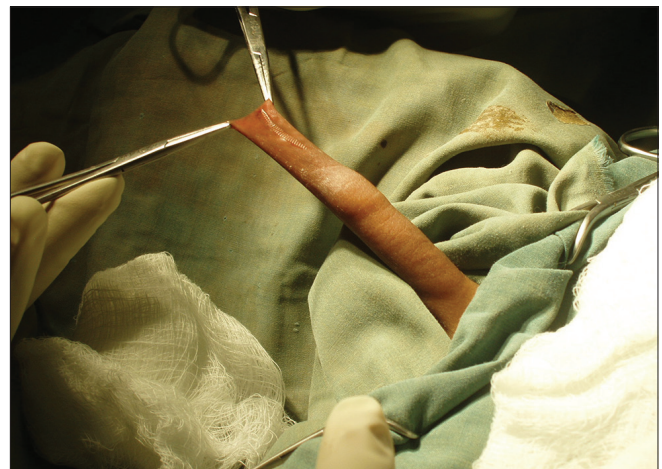

Figure 12: Crushing the prepuce with artery clamp before incision

Most of the infections are minor and of little or no consequence.^[8,12-14] However, major morbidity has been reported, including major skin loss, necrotizing fascitis, staphylococcal scalded skin syndrome, Fournier's gangrene, generalized sepsis, and meningitis. Some of these complications rarely have resulted in severe permanent disability or death.^[14]

Urinary retention

This has been reported following circumcision, usually secondary to a tight circular bandage. In addition, urinary retention secondary to a tight bandage presumably sets the stage for urosepsis in some of the reported cases of systemic infection following circumcision.^[12,14] Reported cases of pain on micturition and hesitancy in older boys following circumcision is quite common.^[12,14]

Fistulas

Urethrocuteaneous fistulas have been reported following circumcision.^[7,8,12-14] Most have occurred with clamp and shield methods of circumcision, but in many instances sutures were placed in the area of the frenulum for control of hemorrhage with inadvertent suturing of the underlying urethra. To prevent this complication, the surgeon should preempt the possibility and visualize exactly what is being done in the course of a circumcision. Incision of unrecognized megalourethra, a congenital malformation of the urethra is the cause in some cases.^[14]

Necrosis

Loss of the glans in part or in whole (commoner) or even entire penis (very rare) due to necrosis and subsequent sloughing has been reported following circumcision.^[14] Distal ischemia producing such tissue loss may result from infection,^[14,23] the use of local anesthetic agents containing adrenaline, attempts at hemostasis with cautery and suture, injudicious and prolonged use of a tourniquet, or from a tight dressing.^[24] In particularly, the use of diathermy with metallic clamps (Gomco) leads to catastrophic loss of the whole phallus.^[14,25-27] On occasions, the tip of the glans has been excised, usually when the operator was using a blind technique.^[24] When the entire penis is lost following such a misadventure, usually it is best to change the child's sex of rearing to female.^[14,25] Such changes are particularly successful when accomplished before 18 months of age.^[14] Necrosis as complication of circumcision is very rare.^[14]

Iatrogenic hypospadias and epispadias

Both hypospadias and epispadias have been reported following circumcision procedure. By inadvertently splitting the glans penis at the time of dorsal or ventral slit preparatory to actual excision of the prepuce,^[27]

these complications can occur. This can be prevented by adequately freeing the prepuce from the glans penis and by visualizing what is being done rather than by performing some aspect of the procedure blindly.^[14,26]

The following complications have also been reported following circumcision, meatitis, chordee, implantation cyst, impotence.^[5,14,28] They are, however, very rare. Weiss *et al.*^[29] in meta-analysis reported a median frequency of 1.5% (range 0-16%) for any complication arising from circumcision. Complication risks and severity is higher in traditional circumcision as a rite of passage than medical circumcision and traditional circumcision in neonates.

CONCLUSION


Male circumcision is performed at any age, there is, however, increasing interest in performing male circumcision in infancy. This is to maximize the benefits conferred by male circumcision and to reduce the risks of adverse events.^[1-2,29] There are various safe and acceptable techniques of achieving male circumcision. The current trend is to have a technique that can be deployed for mass rollout of circumcision in an attempt to prevent transmission of HIV^[2,16,17] and to present an acceptable technique to all so as to encourage worldwide acceptability of the procedure of male circumcision. When performed properly, the procedure has low complication rates. One percent minor complication rate when performed in children and less than 0.5% minor complication when performed in infancy.^[29] Major complications are very rare in hospital setting.^[2-14,29] It is important for the health care providers to acquaint themselves to available procedures for male circumcision. This would aid judgment on choice of procedure for a particular patient thereby improving patients' acceptability of male circumcision.

REFERENCES

- Blank S, Brady M, Buerk E, Carlo W, Diekema D, Freedman A, *et al.* American Academy of Pediatrics, Task force on Circumcision: Male circumcision. *Pediatrics* 2012;130:e756-85.
- Morris BJ, Eley C. Male circumcision: An appraisal of current instrumentation. Chapter 14. In: Biomedical Engineering: From Theory to Applications, Fazel-Rezaei R, editor. Rijeka, Croatia: InTech; 2011. p. 315-54.
- Wiswell TE, Geschke DW. Risks from circumcision during the first month of life compared with those for uncircumcised boys. *Pediatrics* 1989;83:1011-5.
- Wiswell TE, Hachey WE. Urinary tract infections and the circumcision state: An update. *Clin Pediatr (Phila)* 1993;32:130-4.
- Wiswell TE. Neonatal circumcision: A current appraisal. *Focus Opin Pediatr* 1995;1:93-9.
- Wiswell TE. The prepuce, urinary tract infections, and the consequences. *Pediatrics* 2000;105:860-2.
- Tucker SC, Cerqueiro J, Sterne GD, Bracka A. Circumcision: A refined technique and 5 year review. *Ann R Coll Surg Engl* 2001;83:121-5.
- Okeke LI, Asinobi AA, Ikuorowo OS. Epidemiology of complications of

- male circumcision in Ibadan, Nigeria. *BMC Urol* 2006;6:21.
9. Crawford DA. Circumcision: A consideration of some of the controversy. *J Child Health Care* 2002;6:259-70.
 10. Williams N, Kapila L. Complications of circumcision. *Br J Surg* 1993;80:1231-6.1
 11. Weiss H, Polonsky J, Bailey R, Hankins C, Halperin D, Schmid G. Male circumcision: Global trends and determinants of prevalence, safety and acceptability. World Health Organization and the Joint United Nations Programme on HIV/AIDS (UNAIDS) 2007. Available from: http://data.unaids.org/pub/Report/2007/jc1360_male_circumcision_en.pdf. [Last accessed on 2012 Dec 01].
 12. Gerharz EW, Haarmann C. The first cut is the deepest? Medicolegal aspects of male circumcision. *BJU Int* 2000;86:332-8.
 13. Mokai N, Chavan N. Modified safe technique for circumcision. *Indian J Plast Surg* 2008;41:47-50.
 14. Kaplan GW. Complications of circumcision. *Urol Clin North Am* 1983;10:543-9.
 15. Bruhl P. Problems of therapeutic surgery in penis carcinoma. *Recent Results Cancer Res* 1977;60:120-6.
 16. Bitega JP, Ngeruka ML, Hategekimana T, Asiimwe A, Binagwaho A. Safety and efficacy of the PrePex device for rapid scale-up of male circumcision for HIV prevention in resource-limited settings. *J Acquir Immune Defic Syndr* 2011;58:e127-34.
 17. Mutabazi V, Kaplan SA, Rwamasirabo E, Bitega JP, Ngeruka ML, Savio D, *et al*. HIV prevention: Male circumcision comparison between a nonsurgical device to a surgical technique in resource-limited settings: A prospective, randomized, nonmasked trial. *J Acquir Immune Defic Syndr* 2012;61:49-55.
 18. Rickwood AM. Medical indications for circumcision. *BJU Int* 1999;83:45-51.
 19. Brown TC. The anatomy and technique of penile block. *Update Anaesth* 1993;2:11-2.
 20. WHO/UNAIDS/JHPIEGO. Manual for male circumcision under local anaesthesia. Geneva: World Health Organization; 2008. [Last accessed 2012 Dec 01].
 21. Peng Y, Masson P, Li PS, Chang Y, Tian L, Lee R, *et al*. No-needle local anesthesia for adult male circumcision. *J Urol* 2010;184:978-83.
 22. Barrie H, Huntingford PJ, Gough MH. The plastibell technique for circumcision. *BMJ* 1965;2:273-5.
 23. Davidson F. Yeasts and circumcision in the male. *Br J Vener Dis* 1977;53:121-2.
 24. Sterenberg N, Golan J, Ben-Hur N. Necrosis of the glans penis following neonatal circumcision. *Plast Reconstr Surg* 1981;68:237-9.
 25. Money J. Ablatio penis: Normal male infant reassigned as a girl. *Arch Sex Behav* 1975;4:65-71.
 26. Ademuyiwa AO, Bode CO. Complications of neonatal circumcision: Avoiding common pitfalls in a common procedure. *Afr J Paediatr Surg* 2009;6:134-6.
 27. McGowan AJ Jr. A complication of circumcision. *JAMA* 1969;207:2104-5.
 28. Hutcheson JC. Male neonatal circumcision: Indications, controversies and complications. *Urol Clin N Am* 2004;31:461-7.
 29. Weiss HA, Larke N, Halperin D, Schenker I. Complications of circumcision in male neonates, infants and children: A systematic review. *BMC Urol* 2010;10:2.

How to cite this article: Abdulwahab-Ahmed A, Mungadi IA. Techniques of male circumcision. *J Surg Tech Case Report* 2013;5:1-7.
Source of Support: Nil, **Conflict of Interest:** None declared.



"Quick Response Code" link for full text articles

The journal issue has a unique new feature for reaching to the journal's website without typing a single letter. Each article on its first page has a "Quick Response Code". Using any mobile or other hand-held device with camera and GPRS/other internet source, one can reach to the full text of that particular article on the journal's website. Start a QR-code reading software (see list of free applications from <http://tinyurl.com/yzlh2tc>) and point the camera to the QR-code printed in the journal. It will automatically take you to the HTML full text of that article. One can also use a desktop or laptop with web camera for similar functionality. See <http://tinyurl.com/2bw7fn3> or <http://tinyurl.com/3ysr3me> for the free applications.