

# Dentigerous Cyst Associated with Ectopic Canine and a Supernumerary Tooth: A Rare Occurrence

Ashwini Ramakrishna, Pravin Lambade<sup>1</sup>

Departments of Oral Pathology and Microbiology, College of Dental Sciences, Davangere, Karnataka, <sup>1</sup>Oral and Maxillofacial Surgery, Swargiya Dadasaheb Kalmegh Smruti Dental College and Hospital, Nagpur, Maharashtra, India

## INTRODUCTION

Amongst the developmental cysts of the maxillofacial region dentigerous cyst (DC) is the most common.<sup>[1]</sup> The cystic lining is derived from the epithelial remnants of tooth forming organ.<sup>[2]</sup> Second and third decade of life is the common age of occurrence and generally involves the mandibular third molar, maxillary canines and mandibular premolars, followed by supernumerary teeth and central incisor in decreasing order of frequency of involvement.<sup>[3]</sup>

Those teeth located in the jawbones or in regions other than the alveolar arch are said to be ectopically placed. This may be due to irregularity in the migration of a tooth bud which occurs due to genetic/environmental relationship factors causing a budding tooth to congenitally migrate in the initial stages of embryogenesis, or is the result of displacement of the teeth owing to local factors. Volumetric incompatibility between the tooth and dental arch, prolonged retention of primary teeth, presence of clefts, ankylosis, cystic or neoplastic lesion or trauma may be the local factors involved.<sup>[4]</sup> In the permanent dentition, the maxillary canine has the longest path of eruption and this may be an etiology for ectopic placement.<sup>[5]</sup> Supernumerary

## ABSTRACT

Amongst the cysts of the jaw dentigerous cyst (DC) is one of the most prevalent types of odontogenic cysts, which is associated with the crown of an unerupted or developing tooth. DC is more commonly seen with mandibular third molar and maxillary canine and rarely other teeth are involved. These cysts seldom associate with supernumerary teeth. The purpose of this article is to describe a case of large dentigerous cyst associated with supernumerary teeth and an ectopic canine, which is a rare presentation along with its management.

**Key words:** Dentigerous cyst, ectopic teeth, supernumerary teeth

teeth are uncommon, can be ectopically placed and seldom associate with dentigerous cysts.

## CASE REPORT

A 10 year-old boy presented with a painless swelling in the left maxillary anterior region of 8-9 months duration. On general examination, the patient was apparently healthy with normal growth and development for his age and there was no history of systemic diseases or trauma. Clinical examination revealed an extraoral swelling on the left side of the face with elevation of the nostril and lateral border of the nose. The swelling was extending from the lateral wall of the nose to zygomatic region mediolaterally and from infraorbital region to right upper lip superoinferiorly. There was obliteration of the nasolabial fold. The swelling was soft, fluctuant, painless with positive crepitus.

Intraorally the swelling was extending from maxillary left central incisor to the premolar region with obliteration of the vestibule [Figure 1]. The mucosa overlying the swelling appeared to be intact. Paranasal view of the radiograph [Figure 2] showed a well defined unilocular radiolucency surrounding two teeth in the left anterior region of the maxilla. Displacement of the roots of the maxillary left lateral incisor was also seen. The lesion was extending from the lateral wall of the nose to zygomatico maxillary region mediolaterally and from maxillary alveolar ridge to infraorbital rim superoinferiorly.

### Access this article online

#### Quick Response Code:



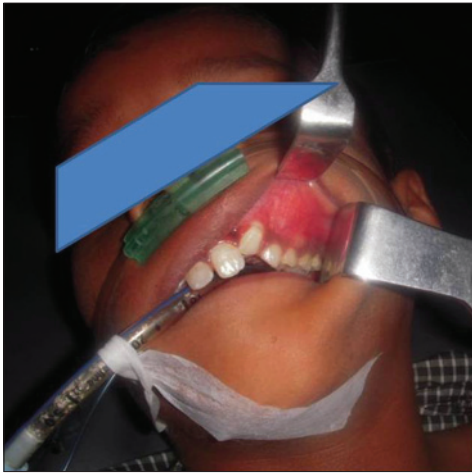
Website:  
www.jstcr.org

DOI:  
10.4103/2006-8808.128738

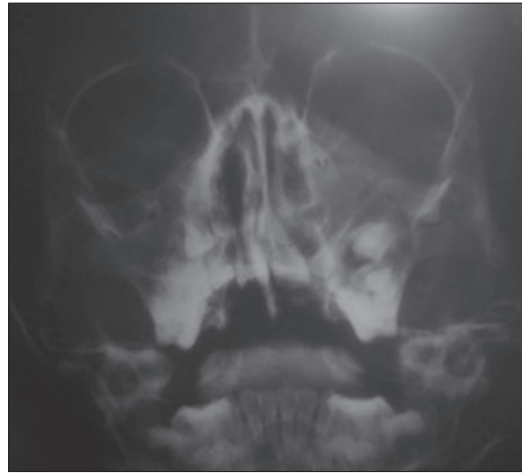
**Address for correspondence:** Dr. Pravin Lambade,  
Department of Oral and Maxillofacial Surgery, Swargiya  
Dadasaheb Kalmegh Smruti Dental College and Hospital,  
Nagpur - 441 110, Maharashtra, India.  
E-mail: drpravinlambade@gmail.com

Fine needle aspiration revealed the presence of straw colored fluid within the lesion. After clinical and radiographic examination, a provisional diagnosis of

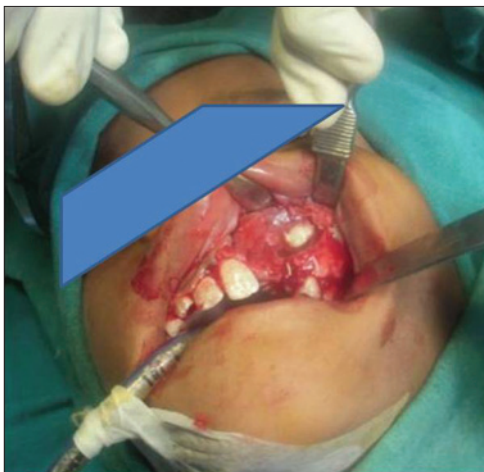
dentigerous cyst involving impacted teeth was made. Routine hematological investigations was normal. Surgical excision of the lesion was planned under general



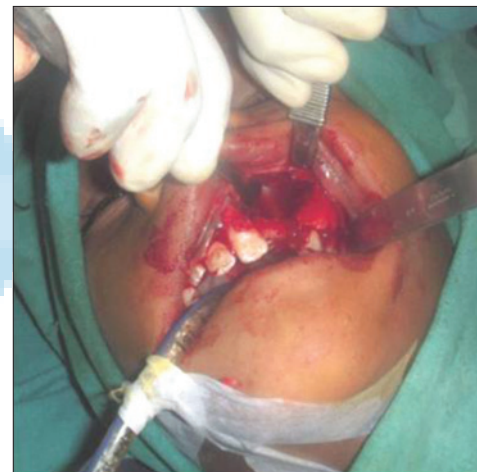**Figure 1:** Pre-operative clinical picture showing swelling in the left maxillary anterior region



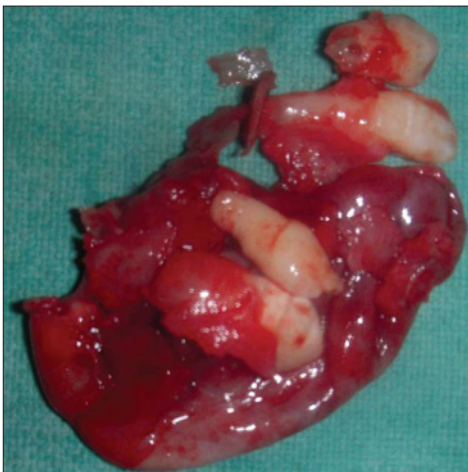
**Figure 2:** Paranasal sinus view showing well defined unilocular radiolucency surrounding the canine and supernumerary teeth



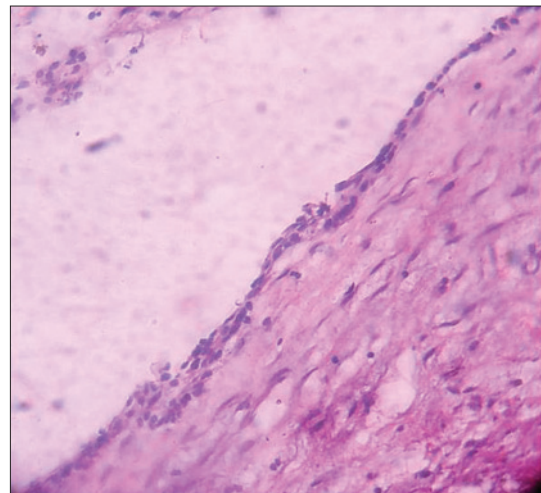
**Figure 3:** Surgical view of the cyst enclosing the impacted teeth



**Figure 4:** Surgical view after complete cyst enucleation



**Figure 5:** Post-operative surgical specimen showing cystic lining along with the extracted teeth (Permanent canine, supernumerary teeth, lateral incisor, retained deciduous canine)



**Figure 6:** Histopathological image of the cystic lining showing features of dentigerous cyst

anesthesia. All aseptic precautions were taken. Crestal incision was given in the region of left maxillary central incisor and extended as crevicular incision around left maxillary first premolar. Vertical releasing incision was given distal to left upper premolar at an angle of 45°. Using a periosteal elevator carefully the full thickness mucoperiosteal flap was raised. On reflection of mucoperiosteum, the exposed buccal cortical plate was found to be very thin and perforated in the region of retained deciduous canine. The cystic lining was located on removal of thin buccal cortical plate. Carefully the cystic lining was separated from the underlying bone along with the impacted teeth (permanent ectopic canine, supernumerary teeth), [Figures 3-5] retained deciduous canine and lateral incisor, which was mobile and involved with the lesion. The supernumerary teeth were conical in shape resembling a peg shaped incisor.

The lesion was found to be measuring around 3 cm × 3 cm, involving the sinus wall. The perforated sinus wall was repaired using autogenous bone graft from anterior sinus wall. Due precaution was taken to avoid perforation or tearing of lateral nasal wall, which was closely attached to the cystic lining. After complete removal of the cystic lining, the mucoperiosteal flap was approximated and suturing done using 3-0 Mersilk. Dressing was given. The post-operative healing was uneventful. The suture removal was carried out after 7 days. Histological examination of the specimen confirmed the diagnosis of a DC [Figure 6]. Patient was under follow-up for 6 months and presented no complications, meanwhile, he was advised for orthodontic and prosthetic rehabilitation to correct the malocclusion and alleviate problems with patients lack of dentition.

## DISCUSSION

Dentigerous cyst has been defined as one which is attached at the cement-enamel junction and encloses the crown of an unerupted tooth. Venous outflow, which is obstructed due to the pressure exerted by potentially erupting tooth on impacted follicle, induces rapid transudation of serum through capillary walls. The increased hydrostatic pressure of this pooling fluid separates the follicle from the crown with or without reduced enamel epithelium.

DC accounts for more than 24% of jaw cysts and is the most common developmental cyst of oral region. A very substantial majority involve mandibular third molar, maxillary permanent canine, followed by mandibular

premolars and maxillary third molars in decreasing order.<sup>[6]</sup> Some of the studies have reported that dentigerous cyst arising from supernumerary teeth account for 5.29-7% of the cases.<sup>[3]</sup>

Patients with DC in maxillary bone or sinus may present with facial swelling, purulent rhinorrhea, nasal obstruction, external nasal deformity and epiphora.<sup>[7]</sup> Panoramic radiograph and upper occlusal radiograph are recommended as first-line diagnostic tools and further evaluation of the lesion by computed tomography examination.<sup>[8]</sup>

There is controversy regarding the management of large residual bony cavities with or without bone grafts. Numerous graft materials such as autografts, allogenic, xenografts and platelet rich plasma are available for the same. The surgical defect of the cystic cavity in our case was 3 cm × 3 cm. Relying on spontaneous bone regeneration no bone graft was used. The post-operative radiographs showed reduction in size of residual cavity and gradual increase in bone density. After 6 months, the healing and spontaneous filling of bone cavity was observed as with the studies of Shokier and Khalifa.<sup>[9]</sup> Long-term lack of dentition in a child may cause psychological or esthetic problems and also functional impairment.

The differential diagnosis of DC includes ameloblastoma, odontogenic keratocyst, odontogenic fibroma, odontogenic myxoma, cementomas and Pindborg tumor.<sup>[10]</sup> Early recognition of the entity and removal is necessary as they may rarely have the potential to develop odontogenic tumors like ameloblastoma and malignancy like squamous cell carcinoma and mucoepidermoid carcinoma. Esthetic and orthodontic problems are encountered when it is associated with anterior teeth. Hence, multidisciplinary management will help in better prognosis of these cases with restoration of esthetics and function.


## REFERENCES

1. Ziccardi VB, Eggleston TI, Schneider RE. Using fenestration technique to treat a large dentigerous cyst. *J Am Dent Assoc* 1997;128:201-5.
2. Amin ZA, Amran M, Khairudin A. Removal of extensive maxillary dentigerous cyst via a Caldwell-Luc procedure. *Arch Orolfac Sci* 2008;3:48-51.
3. John T, Shekhar MG, Koshy M. Dentigerous cyst associated with supernumerary teeth: A report of three cases. *J Clin Diagn Res* 2010;4:2601-6.
4. Dağıstan S, Cakur B, Göregen M. A dentigerous cyst containing an ectopic canine tooth below the floor of the maxillary sinus: A case report. *J Oral Sci* 2007;49:249-52.
5. McSherry PF. The ectopic maxillary canine: A review. *Br J Orthod* 1998;25:209-16.

6. Desai RS, Vanaki SS, Puranik RS, Tegginamani AS. Dentigerous cyst associated with permanent central incisor: A rare entity. J Indian Soc Pedod Prev Dent 2005;23:49-50.
7. Onotai LO, da Lilly-Tariah OB. Dentigerous cyst associated with ectopic tooth at the roof of maxillary sinus. Int J Med Med Sci 2013;3:407-10.
8. Jiang Q, Xu GZ, Yang C, Yu CQ, He DM, Zhang ZY. Dentigerous cysts associated with impacted supernumerary teeth in the anterior maxilla. Exp Ther Med 2011;2:805-9.
9. Shokier HM, Khalifa GA. Assessment of bone healing in large bony defects after enucleation of jaw cysts without using any graft material using direct digital radiography and CT scan. C. D. J 2009;25:35-42.
10. Ngamdu YB, Kodiya AM, Sandabe MB, Garandawa HI, Isa A. Dentigerous cyst associated with ectopic supernumerary canine in the maxillary sinus. J C R 2012;2:27-30.

**How to cite this article:** Ramakrishna A, Lambade P. Dentigerous cyst associated with ectopic canine and a supernumerary tooth: A rare occurrence. J Surg Tech Case Report 2013;5:85-8.

**Source of Support:** Nil, **Conflict of Interest:** None declared.



#### Announcement

##### Android App



Download  
**Android  
application**

FREE

A free application to browse and search the journal's content is now available for Android based mobiles and devices. The application provides "Table of Contents" of the latest issues, which are stored on the device for future offline browsing. Internet connection is required to access the back issues and search facility. The application is compatible with all the versions of Android. The application can be downloaded from <https://market.android.com/details?id=comm.app.medknow>. For suggestions and comments do write back to us.