

Intraoperative Development of Tension Pneumocephalus in a Patient Undergoing Repair of a Cranial-dural Defect Under Nitrous Oxide Anesthesia

Mansher Singh, Viren S. Vasudeva¹, Arturo J. Rios Diaz², Ian F. Dunn¹, Edward J. Caterson

Division of Plastic Surgery, Departments of ¹Neurosurgery and ²Surgery, Center for Surgery and Public Health, Brigham and Women's Hospital, Boston, MA 02115, USA

INTRODUCTION

Pneumocephalus is characterized by the presence of air within the cranial vault and can be subdural, subarachnoid, epidural, intraventricular, or intraparenchymal depending on the location of the air.^[1,2] Possible etiologies of pneumocephalus include cranial trauma, neoplasm, and infection. Pneumocephalus is also seen in nearly all patients following craniotomy.^[3] Under normal circumstances, pneumocephalus is asymptomatic; however, rapid expansion of a trapped air cavity within the cranial vault can create a mass effect on the brain and result in intracranial hypertension. This condition, termed "tension pneumocephalus," is a neurosurgical emergency and if left untreated may cause rapid neurological deterioration, herniation, and death.^[4-6]

Nitrous oxide (N₂O), often administered as a component of general anesthesia, has also been implicated in pneumocephalus.^[7-9] Since the blood: Gas coefficient of N₂O is almost 34 times more than nitrogen, it would diffuse from blood into a closed space (such as cranial vault) at significantly faster rate than the nitrogen/air would exit from the closed space into the blood.^[10] This would

ABSTRACT

Rapid buildup of gas within the cranial vault can result in a life-threatening condition known as "tension pneumocephalus," necessitating immediate surgical intervention. Nitrous oxide (N₂O), a commonly used inhaled anesthetic, is associated with the development of tension pneumocephalus and its role in neurosurgical procedures has been debated in the literature. We present a case of tension pneumocephalus with preexisting pneumocephalus secondary to the usage of N₂O as an inhaled anesthetic. Included is a literature review of studies discussing the role of N₂O in the development of tension pneumocephalus. N₂O is associated with tension pneumocephalus especially in the setting of preexisting pneumocephalus. Tension pneumocephalus can manifest as Cushing response and immediate decompression is life-saving. Nitrous oxide should be used cautiously in neurosurgical procedures, especially with preexisting pneumocephalus.

Key words: Nitrous oxide, inhaled anesthetic, tension pneumocephalus

result in increased volume of gas in the closed space. In a noncompliant space such as a cranial vault, the increase in volume is restricted. Hence, with increased amount of intracranial gas, there is a severe and rapid increase in intracranial pressure (ICP), especially with a preexisting pneumocephalus.^[11-13]

We present a case of intra-operative tension pneumocephalus secondary to N₂O in a patient with preexisting pneumocephalus and a history of ventriculoperitoneal (VP) shunt and two right parietal craniotomies for resection of glioblastoma multiforme (GBM). A review of studies discussing the role of N₂O in tension pneumocephalus has also been included. The article heightens awareness among

This is an open access article distributed under the terms of the Creative Commons Attribution-NonCommercial-ShareAlike 3.0 License, which allows others to remix, tweak, and build upon the work non-commercially, as long as the author is credited and the new creations are licensed under the identical terms.

For reprints contact: reprints@medknow.com

How to cite this article: Singh M, Vasudeva VS, Rios Diaz AJ, Dunn IF, Caterson EJ. Intraoperative development of tension pneumocephalus in a patient undergoing repair of a cranial-dural defect under nitrous oxide anesthesia. J Surg Tech Case Report 2015;7:20-2.

Access this article online

Quick Response Code:



Website:

www.jstcr.org

DOI:

10.4103/2006-8808.184942

Address for correspondence: Dr. Edward J. Caterson, Division of Plastic Surgery, Brigham and Women's Hospital, Harvard Medical School, 75 Francis Street, Boston, MA 02115, USA.
E-mail: ecaterson@partners.org

neurosurgeons and anesthesiologists of the potential risk of tension pneumocephalus, while using N_2O especially in the context of preexisting pneumocephalus.

CASE REPORT

The patient was a 61-year-old male who was diagnosed with right temporoparietal GBM and treated with right temporoparietal resection and adjuvant chemo-radiation. Unfortunately, he developed recurrence of his tumor and was re-operated for recurrent tumor and ultimately started on avastin chemotherapy. During a routine follow-up magnetic resonance imaging, he was found to have a right middle cerebral artery pseudoaneurysm for which he required another craniotomy for definitive obliteration of the pseudoaneurysm. He then developed wound dehiscence with cerebrospinal fluid (CSF) leak, which was likely from a combination of steroid use, prior irradiation, multiple operations through the same incision, and avastin use – the latter, through its anti-angiogenic properties, is particularly harmful to healing incisions. He underwent wound debridement with the removal of his bone flap and previously placed titanium hardware and a titanium cranioplasty was done along with multiple layered scalp closure. He continued to have multiple episodes of CSF leak over next few months with elevated spinal fluid pressure on multiple lumbar punctures. Given the diminished wound leakage with lumbar drainage, a VP shunt was placed for definitive CSF diversion. He was discharged after uneventful recovery, but returned 5 days later with acute onset left sided weakness on his upper and lower extremity along with decreased sensation on the entire left side. A head computed tomography (CT) scan was obtained which revealed significant right-sided tension pneumocephalus beneath his craniotomy site. He was emergently operated on for right parietal craniotomy for the relief of his tension pneumocephalus. Intra-operatively, he was found to have frank wound dehiscence and his previous craniotomy wound was debrided and replaced with a new titanium implant measuring 6 cm × 6 cm. The overlying skin was closed with a running 5-0 prolene for watertight closure. He was discharged after resolution of his symptoms and uneventful recovery.

He continued to have a nonhealing portion in the central portion of his incision with a small opening which was being managed conservatively. Unfortunately, he presented again to the emergency room with left sided numbness and weakness with gait instability. A CT scan was done which demonstrated concern for acute pneumocephalus [Figure 1]. He was taken to the operating room for exploration and large scalp rotational flap based

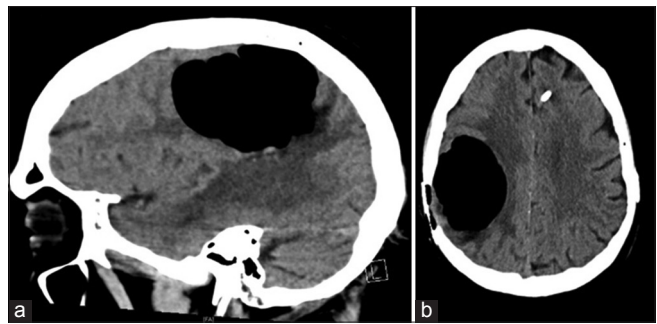


Figure 1: Sagittal (a) and axial (b) sections of computed tomography scan demonstrating pneumocephalus in the index patient

on the superficial temporal artery for definitive closure of another episode of wound dehiscence. However, while the patient was undergoing debridement and prior to entering his old resection cavity, he was receiving N_2O as a part of his general anesthesia. At this point, his brain was noted to be incredibly tense which was significantly different from the start of the operation. His blood pressure was significantly elevated and his heart rate dropped to 40 s raising the concern of tension pneumocephalus and Cushing phenomenon. The N_2O was immediately discontinued and emergently the old tumor cavity was entered with a curved snap followed by a forceful large “whooshing” sound, indicating escape of a large amount of trapped intracranial air (cerebral flatulence). Following this maneuver, his heart rate returned to the normal range and the vital signs were reversed from the Cushing phenomenon. The remainder portion of the surgery was uneventful and the wound was covered with superficial temporalis artery-based flap. N_2O had been discontinued. The patient had an unremarkable postoperative recovery and discharged 5 days postoperatively. However, his tumor continued to progress resulting in worsening neurological dysfunction and he died 24 months later from progressive illness.

DISCUSSION

Nitrous oxide is used in combination with other general anesthetic agents since it helps in rapid onset and termination of anesthetic effects and has minimal effect on the blood pressure. The rapid onset of anesthesia with N_2O can be attributed to smaller blood-gas partition coefficients (0.47) compared to other inhalational agents. Blood-gas partition coefficient is defined as the ratio of the concentration in blood to the concentration in gas that is in contact with that blood, when the partial pressure in both compartments is equal. During the anesthetic administration, a significant amount of N_2O enters closed gas spaces. These spaces mainly contain nitrogen (from air), whose low blood/gas partition coefficient (0.013)

limits its removal by blood. Thus, the rate of entrance of N₂O into the closed gas spaces is significantly more than the exit of nitrogen from the closed gas space to the blood stream, resulting in a rapid increase in volume.^[10] In a nondistensible cavity like cranial vault, such rapid increase of volume could result in “tension pneumocephalus” especially with preexisting pneumocephalus. Based on this argument, it is recommended to avoid N₂O altogether or discontinue its use prior to the dural closure.^[9] The rationale behind discontinuing the usage of N₂O until dural closure is that a pneumocephalus formed intraoperatively would mainly contain N₂O, which would then be reabsorbed rapidly into the blood on discontinuation of N₂O due to the concentration gradient.^[14] However, this has been questioned with conflicting reports in the literature.^[15-18] The most significant study refuting the role of N₂O in tension pneumocephalus was published by Domino *et al.* who demonstrated that there was no difference in the ICP when the patients undergoing elective craniotomy were randomized to continuing N₂O following dural closure versus replacing the N₂O with nitrogen before the dural closure.^[15] In another study published by Friedman, discontinuation of N₂O 30 min before the dural closure did not seem to have any preventive effect on tension pneumocephalus.^[16]

However, Artru reported more than two-fold increase in the ICP on continuation of N₂O on dural closure which got back to normal reference range on discontinuing N₂O.^[8] Few other studies also demonstrated a temporal increase in ICP with N₂O intra-operatively and reversal of increased ICP on discontinuation of N₂O.^[9,17] Since then, N₂O has been implicated as a cause of tension pneumocephalus in other case reports.^[11,12,18,19]

A history of multiple craniotomies, radiation to the brain, steroid use, and avastin administration contributed to wound dehiscence in our patient, which resulted in a communication between the intra-cranial resection cavity and the external environment. Negative pressure created by the VP shunt – placed to divert CSF away from the incision and prevent meningitis – further conspired to the ingress of atmospheric air into intracranial cavity resulting in two episodes of tension pneumocephalus in our patient. However, during the second episode, there was a definite acute increase in ICP after inadvertent N₂O inhalation as evidenced by extremely tense brain and a clear Cushing response. Return of vital signs to normal range after releasing the pressure and discontinuation of N₂O further confirms the role of N₂O in tension pneumocephalus. Our study supports the association of N₂O with tension

pneumocephalus especially in the setting of preexisting pneumocephalus. While it might be reasonable to use N₂O in elective craniotomy cases, it should be discontinued prior to the dural closure and it should be avoided in the setting of known pneumocephalus.

Financial support and sponsorship

Nil.

Conflicts of interest

There are no conflicts of interest.

REFERENCES

1. Wolff E. Luftansammlung im rechten seitenventrikel des gehirns (Pneumocephalus). Münch Med Wochenschr 1914;61:899.
2. Schirmer CM, Heilman CB, Bhardwaj A. Pneumocephalus: Case illustrations and review. Neurocrit Care 2010;13:152-8.
3. D'Addario R, Greenberg J, O'Neill TJ, Spagna P. Pneumocephalus: An unusual cause. J Neurol Neurosurg Psychiatry 1974;37:271-4.
4. Ectors PM. Postoperative tension pneumocephalus. J Neurosurg 1988;69:641-2.
5. Toung T, Donham RT, Lehner A, Alano J, Campbell J. Tension pneumocephalus after posterior fossa craniotomy: Report of four additional cases and review of postoperative pneumocephalus. Neurosurgery 1983;12:164-8.
6. Sprague A, Poulgrain P. Tension pneumocephalus: A case report and literature review. J Clin Neurosci 1999;6:418-24.
7. Saidman LJ, Eger EI. Change in cerebrospinal fluid pressure during pneumocephalography under nitrous oxide anesthesia. Anesthesiology 1965;26:67-72.
8. Artru AA. Nitrous oxide plays a direct role in the development of tension pneumocephalus intraoperatively. Anesthesiology 1982;57:59-61.
9. Skahen S, Shapiro HM, Drummond JC, Todd MM, Zelman V. Nitrous oxide withdrawal reduces intracranial pressure in the presence of pneumocephalus. Anesthesiology 1986;65:192-5.
10. Schuh FT. Side effects of nitrous oxide (author's transl). Anaesthesist 1975;24:392-9.
11. Mallamo JR, Hubbard RB, Boone SC, Reisner LS, Pister JD. Expansion of an air-filled subdural space during nitrous oxide anesthesia. Radiology 1975;115:369-72.
12. Raggio JF, Fleischer AS, Sung YF, Hoffman JC. Expanding pneumocephalus due to nitrous oxide anesthesia: Case report. Neurosurgery 1979;4:261-3.
13. Pandit UA, Mudge BJ, Keller TS, Samra SK, Kilaru P, Pandit SK, *et al.* Pneumocephalus after posterior fossa exploration in the sitting position. Anaesthesia 1982;37:996-1001.
14. Friedman GA. Nitrous oxide and the prevention of tension pneumocephalus after craniotomy. Anesthesiology 1983;58:196-7.
15. Domino KB, Hemstad JR, Lam AM, Laohaprasit V, Mayberg TA, Harrison SD, *et al.* Effect of nitrous oxide on intracranial pressure after cranial-dural closure in patients undergoing craniotomy. Anesthesiology 1992;77:421-5.
16. Friedman GA, Norfleet EA, Bedford RF. Discontinuance of nitrous oxide does not prevent tension pneumocephalus. Anesth Analg 1981;60:57-8.
17. Frost EA. Nitrous oxide and intraoperative tension pneumocephalus. Anesthesiology 1983;58:197.
18. Sprehn M, Faber T, Osgaard O. Life-threatening tension pneumocephalus after nitrous oxide anaesthesia. Anaesthesia 1992;47:174.
19. Theilen HJ, Heller AR, Litz RJ. Nitrous oxide-induced tension pneumocephalus after thoracic spinal cord surgery: A case report. J Neurosurg Anesthesiol 2008;20:211-2.