

CASE REPORT

OPEN ACCESS
Full open access to this and thousands of other papers at <http://www.la-press.com>.

Crossplasty: An Alternative Technique for Closing Double Defects

Ibrahim K. Al Aradi and Wael M. El-Shafei

Dermatologic Surgery Unit, Asa'ad Al-Hamad Dermatology Center, Al-Sabah Hospital, PO Box 106 Salimya, Kuwait 22002.
Email: ialaradi@hotmail.com

Abstract: Crossplasty is a modified O-T advancement flap. It is an alternative technique to close double surgical defects, which are arranged in a vertical line. It is useful to camouflage the scar in forehead parallel lines. Geometrically, it is an inverted T joined to a vertical linear defect. There are three important pre-requisites to this technique: an extensive undermining to all flap limbs, excision of the middle zone normal skin and the purse string stitch of the central zone of the flap.

Keywords: double defects, advancement forehead flap, purse string stitches

Clinical Medicine: Dermatology 2009;2 27–30

This article is available from <http://www.la-press.com>.

© the authors, licensee Libertas Academica Ltd.

This is an open access article distributed under the terms of the Creative Commons Attribution License (<http://www.creativecommons.org/licenses/by/2.0>) which permits unrestricted use, distribution and reproduction provided the original work is properly cited.

This article discusses closure options for vertically arranged double surgical defects of unequal size on the forehead. Primary closure of two defects close to each other may be difficult because of the excessive tension on the cutaneous bridge between the two defects. Two adjacent defects can be closed using a Burow's triangle advancement flap in which the advanced Burow's triangle contains the second defect. However this cannot be applied to our patient because it will distort the adjacent structures.¹

Double advancement flap is another option after removal of the cutaneous bridge between the two unequal defects. This will lead to more tissue loss, more back-cuts, parallel cuts and require four Burow's triangles to eliminate standing cones of redundant tissue. These additional incisions lead to further compromise perfusion to the tip of the flap, add to the number of scars and provide less camouflage.²

Another option is the use of expansion to reconstruct forehead defects.³ The disadvantages of this procedure include temporary cosmetic deformity during the expansion phase, prolonged periods required for expansion, the need for multiple procedures and complications associated with the implant and placement.⁴ Advancement flaps are the simplest type of flap to perform. An O-T flap involves construction of the flap by making an incision along the base of the imagined triangular defect and then joining the two basal tips of the triangle with the mid point of the base. The O-T flap helps to avoid distortion of adjacent structure located on one edge of the defect.⁵

Crossplasty is a modified O-T advancement flap. It is an alternative technique to close double surgical defects, which are arranged in a vertical line. It is useful to camouflage the scar in the forehead parallel lines. Geometrically, it is an inverted T joined to a vertical linear defect. There are three important prerequisites to this technique: an extensive undermining to all flap limbs, the excision of the middle zone normal skin and the purse string stitch of the central zone of the flap.

Technique

A 57 years old male presented with two erythematous scaly papules in the left side of the forehead. They were lined in a vertical position (Fig. 1). The upper one measured 1.1 cm × 1.5 cm while the lower one measured 1.1 cm × 1.3 cm. Skin biopsies revealed

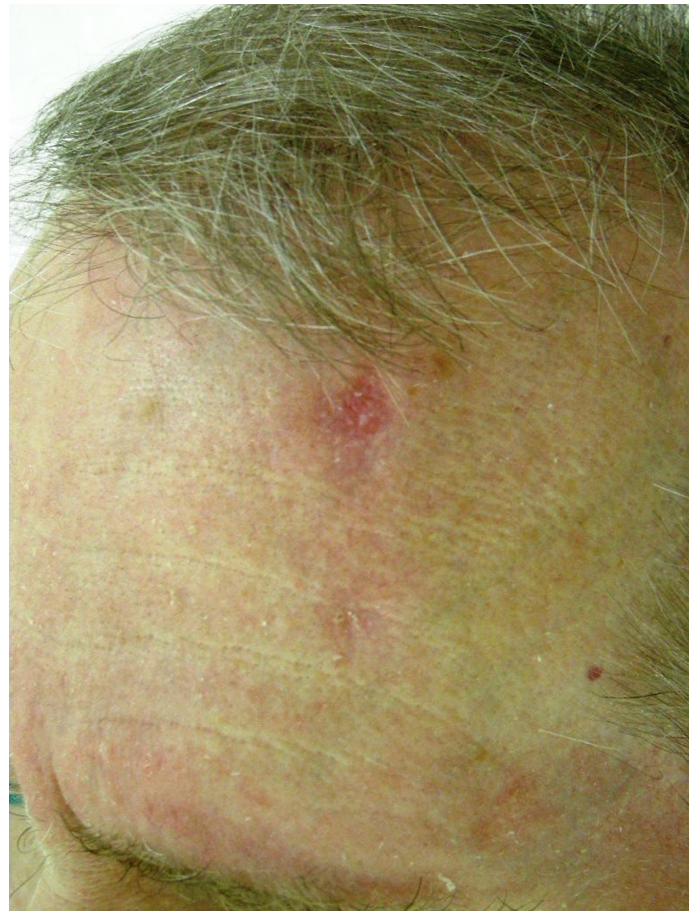

Figure 1. A 57 years old male, presented with two erythematous scaly papules in the left side of the forehead. Skin biopsies of both lesions showed upper nodular and lower infiltrative type basal cell carcinomas. Both lesions are lined up in a vertical position.

nodular basal cell carcinoma of the upper lesion and infiltrative basal cell carcinoma of the other lesion. Since both lesions were ill-defined, and the lower skin lesion being an infiltrative type Mohs Micrographic surgery was indicated to reduce the risk of recurrence of such tumors. The upper nodular basal cell carcinoma was excised completely and microscopy indicated the remaining area free of tumor cells after removal of the first level by Mohs micrographic surgery. The lower skin lesion was positive for infiltrative basaloid cells, after the third Mohs level but was found to be negative after the final fourth level. Postoperatively, there were two cutaneous defects of 2.0 cm × 1.2 cm and 3.0 cm × 3.0 cm in the upper and lower positions consecutively (Fig. 2A). These defects were separated by 0.7 × 1.3 cm cutaneous bridge. An extensive subcutaneous undermining of the superficial fatty tissue of about 1.5 cm

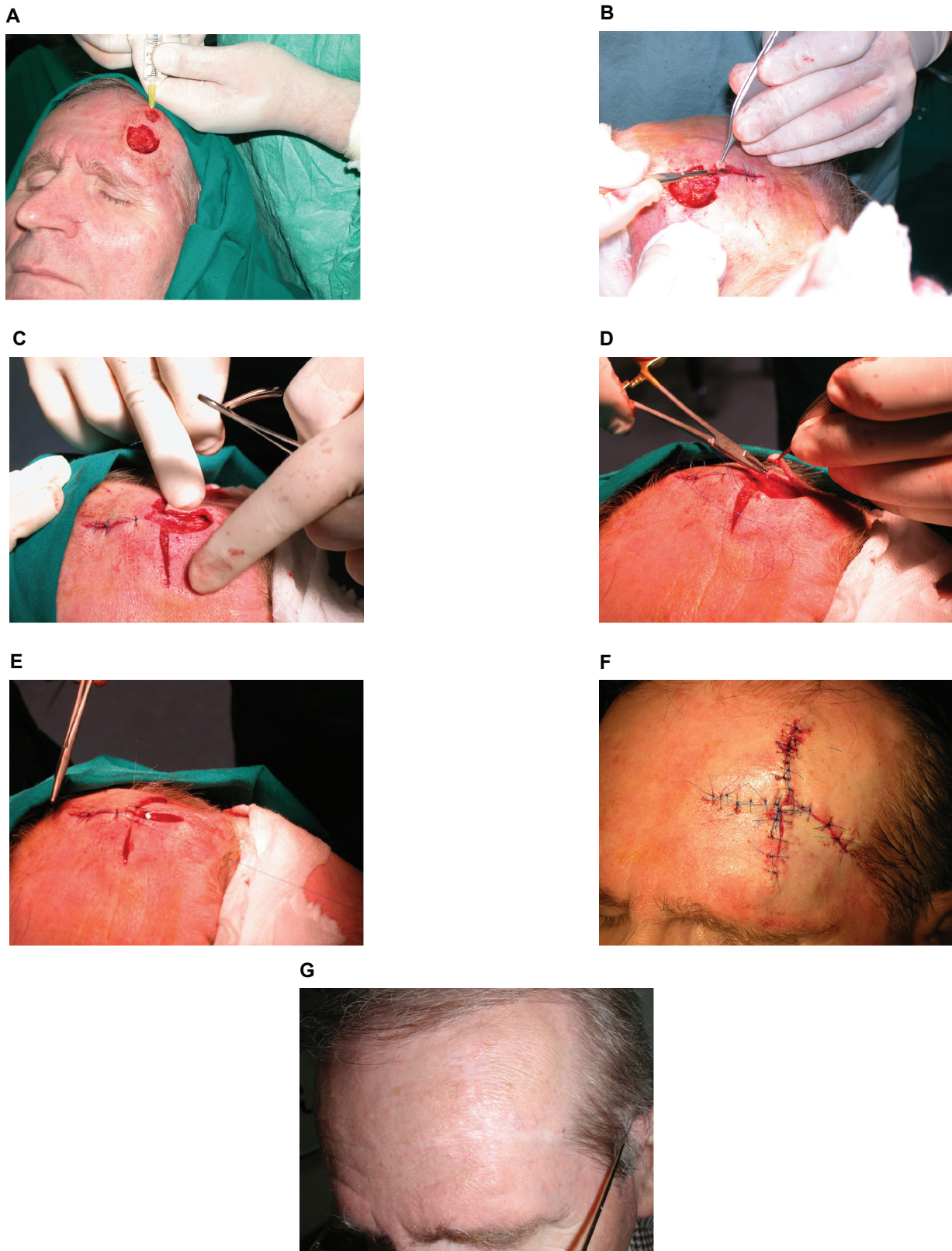


Figure 2. Mohs Micrographic surgery was used to clear both malignant tumors. **A)** Postoperatively, there were two circular defects, upper 2.0×1.2 cm and lower 3.0×3.0 cm defects. **B)** Extensive undermining of both defects was required to close the upper defect. This was done by primary closure. The redundant dog ear, middle zone of normal skin, was excised. **C)** Two horizontal incisions were made along the forehead lines. The O-T advancement flap limbs were released through undermining of the superficial fatty layer. **D)** and **E)** Purse string key stitches were crucial to secure the flap hinge. **F)** The surface of the defects was closed through interrupted non absorbable matrices. **G)** After six months, both defects healed with an acceptable scar in the forehead.



was performed around the defects. We attempted to join the two defects through the subcutaneous undermining. The upper defect was closed by a simple closure. The lower dog ear was excised in a second attempt to join the two defects (Fig. 2B). Two incisions along the forehead parallel lines were performed in the upper border of the lower defect (Fig. 2C). Undermining of the incisions and neighboring subcutaneous tissues was useful to create the central flap limbs. Purse string stitches were useful to secure the hinge of the O-T flap (Figs. 2D and E). The surface of the defects were closed by interrupted matrices (Fig. 2F). An inferior dog ear redundancy was noted. Compressive bandaging was used to dress the wound. A follow-up visit after 6 months indicated good results (Fig. 2G).

Conclusion

In summary, a modified O-T advanced flap, cross-plasty, is presented in this article which indicates a good technique to close vertically arranged double surgical defects of an unequal size. It is an aesthetically acceptable and safe technique. On the forehead it is performed to avoid distortion of adjacent structures like the eye brow hairline and to decrease the tension between the defects. It is also useful in camouflage the scar within the forehead parallel lines.

Disclosures

The authors have indicated no significant interest with commercial supporters.

References

1. Boggio P, Gattoni M, Zanetta R, Leigh G. Burow's triangle advancement flaps for excision of two closely approximated skin lesions. *Dermatol Surg.* 1999;25:622–5.
2. Nouri K, Leal-Khoury S, Khouri R. *Techniques in Dermatologic Surgery.* London: Mosby. 2003:141–51.
3. Iwahira Y, Maruyama Y. Expanded unilateral forehead flap (Sail Flap) for coverage of opposite forehead defects. *Plast Reconstr Surg.* 1993;92(6): 1052–6.
4. Manders EK, Schenden MJ, Furrey JA, et al. Soft tissue expansion concepts and complications. *Plast Reconstr Surg.* 1984;74(4):493–507.
5. Krishnan R, Garman M, Nunez-Gussman J, Orengo I. Advancement Flaps: A basic theme with many variations. *Dermatol surg.* 2005;31(8 Ptz): 986–94.

Publish with Libertas Academica and every scientist working in your field can read your article

"I would like to say that this is the most author-friendly editing process I have experienced in over 150 publications. Thank you most sincerely."

"The communication between your staff and me has been terrific. Whenever progress is made with the manuscript, I receive notice. Quite honestly, I've never had such complete communication with a journal."

"LA is different, and hopefully represents a kind of scientific publication machinery that removes the hurdles from free flow of scientific thought."

Your paper will be:

- Available to your entire community free of charge
- Fairly and quickly peer reviewed
- Yours! You retain copyright

<http://www.la-press.com>